

Contents

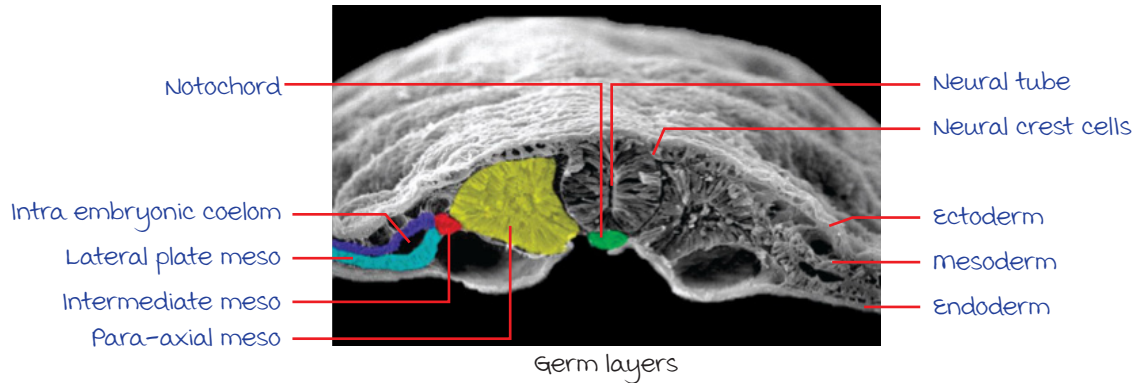
Embryology	1
Thorax	10
Abdomen	16
Head, Neck and Face	22
Neuroanatomy : Part 1	30
Neuroanatomy : Part 2	35
Upper Limb : Part 1	41
Upper Limb : Part 2	46
Lower Limb : Part 1	49
Lower Limb : Part 2	54

EMBRYOLOGY

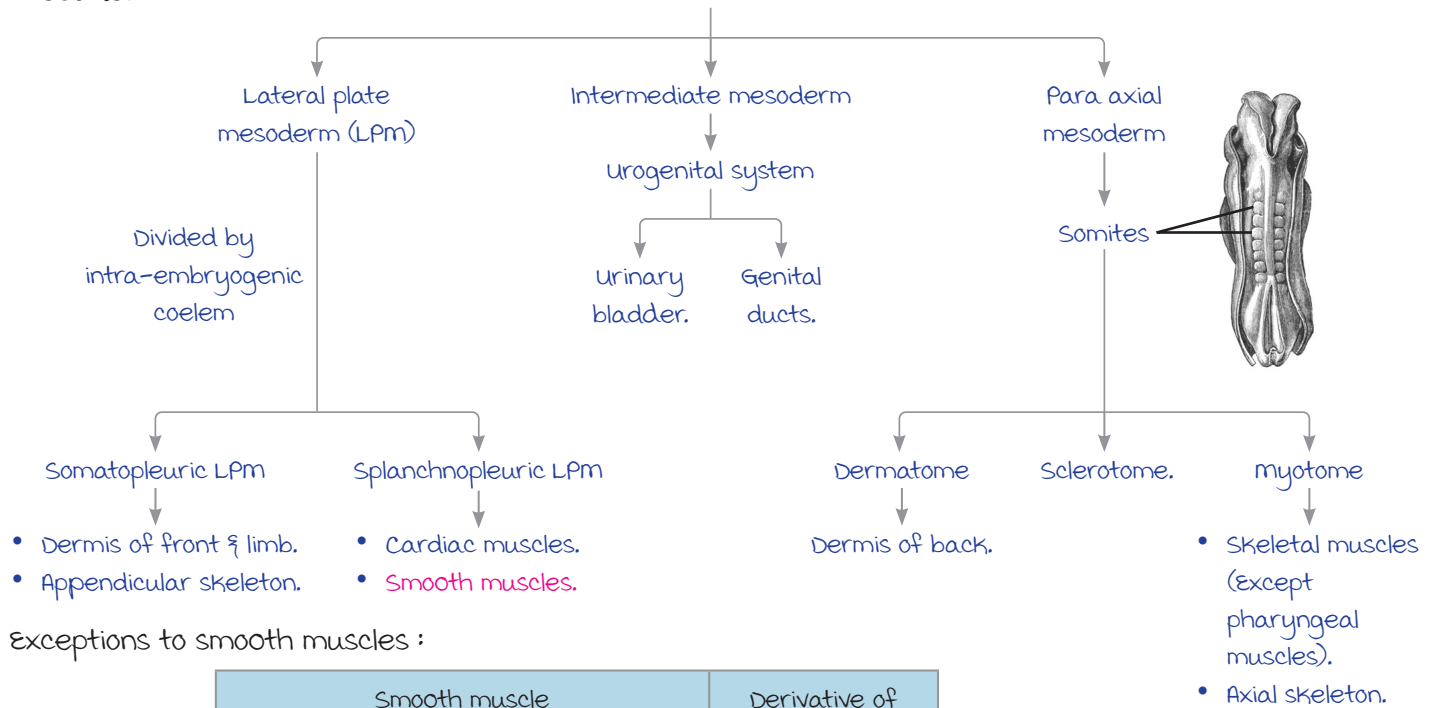
----- Active space -----

Development of Germ Layers

00:00:23



mesoderm :



Exceptions to smooth muscles :

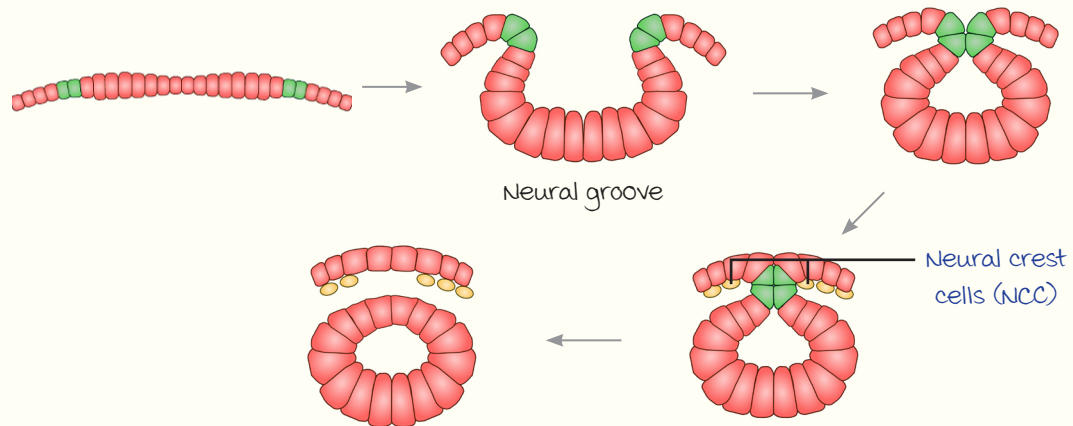
Smooth muscle	Derivative of
<ul style="list-style-type: none"> Smooth muscles of ascending aorta, pulmonary trunk, coronary artery Ciliaris muscle 	Neural crest cells
<ul style="list-style-type: none"> Sweat gland mammary gland 	Ectoderm
<ul style="list-style-type: none"> Sphincter & dilator pupillae 	Neuroectoderm

----- Active space -----

Neural Tube :

Formation :

Formed by stimulation of ectoderm by notochord.



Remnants of notochord :

1. Apical ligament of dens.
2. **Nucleus pulposus** (Central part of intervertebral disc).
3. Tectorial membrane (Continuation of posterior longitudinal ligament).

Derivatives :

Forms CNS structures :

- Brain & spinal cord.
- Oligodendrocytes (myelination).
- Astrocytes (Blood brain barrier).
- Ependymal cells (Lining of ventricles).
- Retina & pigment.

Note :

Intervertebral disc : 2 parts.

- Outer : Annulus fibrosus.
- Central : Nucleus pulposus.

Neural Crest Cells (NCC) :

Present at the junction of neural tube & ectoderm.

Structures formed

PNS structures :

- All ganglion.
- Enteric plexus.
- Schwann cells.
- Adrenal medulla.
- Para-follicular-C cells.
- melanoblast/cyte.

Derivatives of head & neck :

- Skull bones (most).
- Dentine (Odontoblasts).
- Pharyngeal arch cartilage.
- Dermis of head & neck.
- Conotruncal septum.

Note : Adrenal cortex → Derivative of intermediate mesoderm.

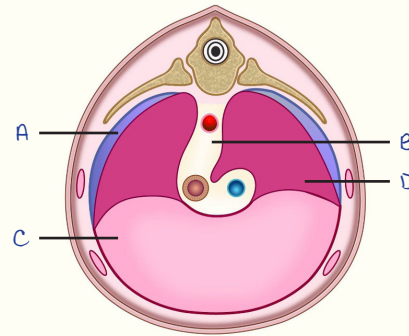
Development of Diaphragm

00:16:08

----- Active space -----

Derivatives :

	Structure	Derivative
A	Body wall mesoderm/ cervical somites	muscles of diaphragm
B	Dorsal mesentery of esophagus	Crus of diaphragm
C	Septum transversum	Central tendon
D	Pleuroperitoneal membrane	Incorporated by muscles



Applied Anatomy :

Congenital diaphragmatic hernia :

- Occurs d/t absence of pleuroperitoneal membrane



Persistence of pleuroperitoneal canal (Bochdalek foramen)



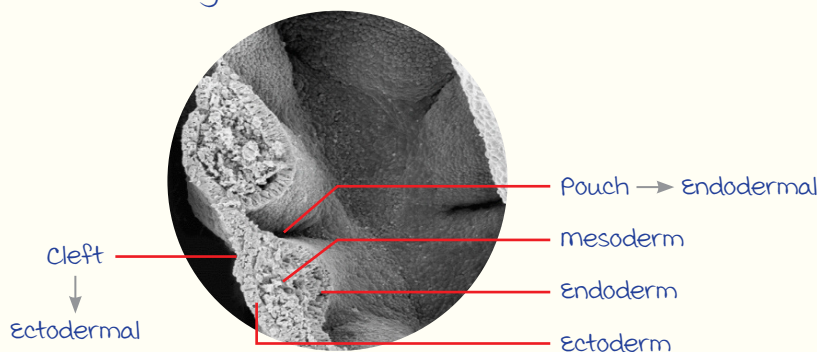
Intestinal herniation.

- **Left** > Right.
- Complication : **Lung hypoplasia.**

Pharyngeal Arches

00:20:45

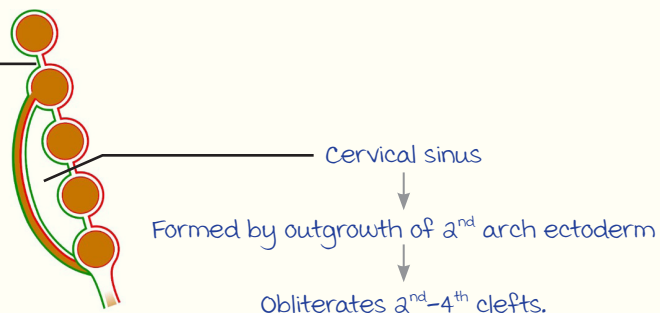
Core of mesoderm, lined by ectoderm on one side & endoderm on the other.



Pharyngeal Clefts :

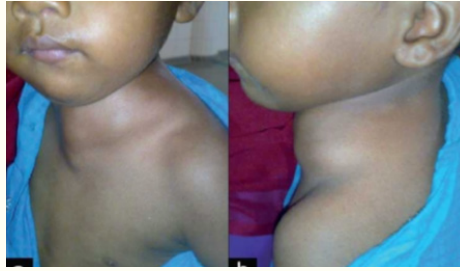1st cleft :

- Only cleft that persists.
- Derivatives :
 - External auditory canal.
 - Outer layer of tympanic membrane.



----- Active space ----- Applied anatomy :

Persistence of cervical sinus → Branchial cyst : Swelling along sternocleidomastoid.



Pharyngeal Pouches :

Pouch	Derivatives
1	<ul style="list-style-type: none"> • Inner layer of tympanic membrane • Tympanic cavity • Auditory tube/eustachian tube • mastoid antrum
2	<ul style="list-style-type: none"> • Palatine tonsil
3	<ul style="list-style-type: none"> • Thymus • Inferior parathyroid
4	<ul style="list-style-type: none"> • Superior parathyroid
Remnant of 5 th pouch	<ul style="list-style-type: none"> • Ultimobranchial body

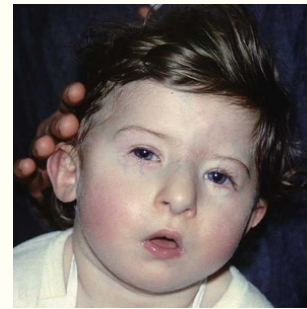Note :

C-cells : Derived from NCC > Ultimobranchial body.

Applied anatomy :

DiGeorge syndrome :

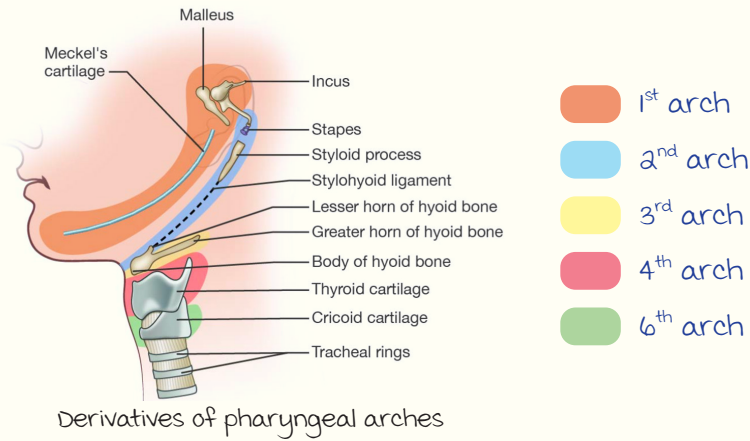
- Anomaly of 3rd > 4th pouch.
- m/c micro-deletion syndrome : 22q11 deletion.
- Absent thymus & hypoparathyroidism.



DiGeorge syndrome

Pharyngeal Arch Cartilages

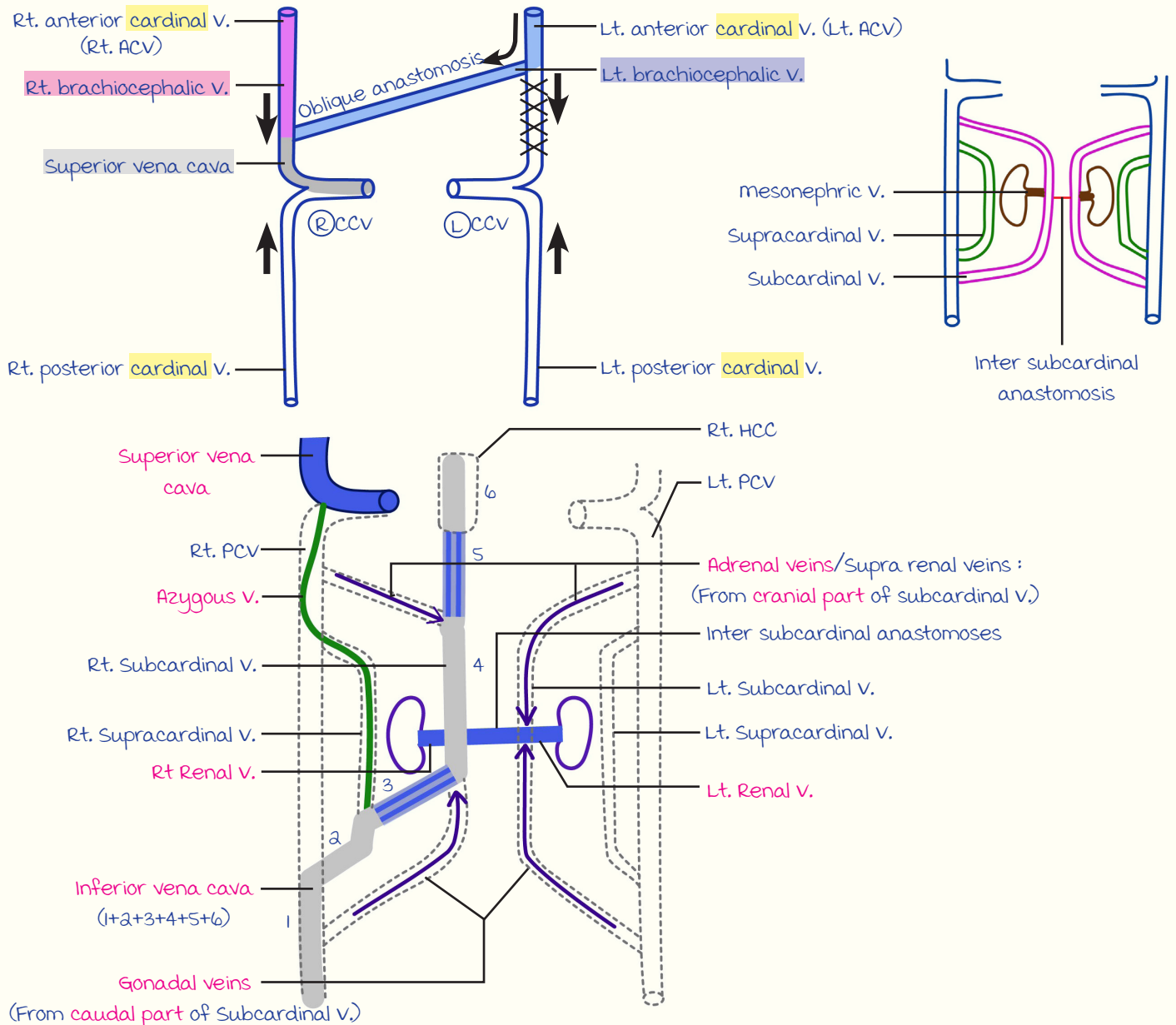
Arch	Derivative structures
1	<ul style="list-style-type: none"> • meckel's cartilage → malleus & incus • mandible
2	<ul style="list-style-type: none"> • Stapes (except footplate : Derived from otic capsule) • Styloid process • Stylohyoid ligament • Lesser cornua of hyoid
3	<ul style="list-style-type: none"> • Greater cornua of hyoid • Body of hyoid
4 & 6	<ul style="list-style-type: none"> • Laryngeal cartilages



Arterial & Venous Development

00:31:23

VENOUS DEVELOPMENT



----- Active space -----

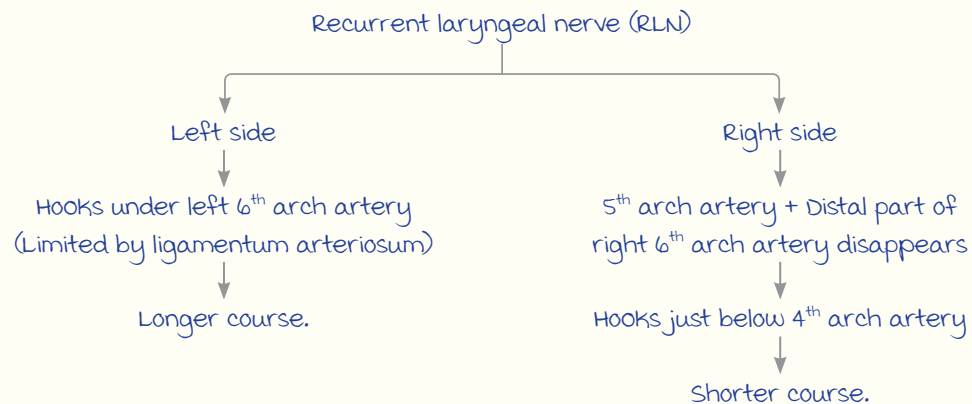
Vein		Derivative of
Rt. brachiocephalic vein		Right ACV
Lt. brachiocephalic vein		Left ACV + Oblique anastomosis
Superior vena cava		Right ACV + Right CCV
Inferior vena cava		Right PCV Right supracardinal ↕ ⊕ Anastomosis Right subcardinal
Renal vein	Right	Right mesonephric vein
	Left	Left mesonephric vein + Intersubcardinal anastomosis
Azygos vein		Right supracardinal vein > Right PCV
Gonadal vein		Caudal part of subcardinal vein
Adrenal vein		Cranial part of subcardinal vein

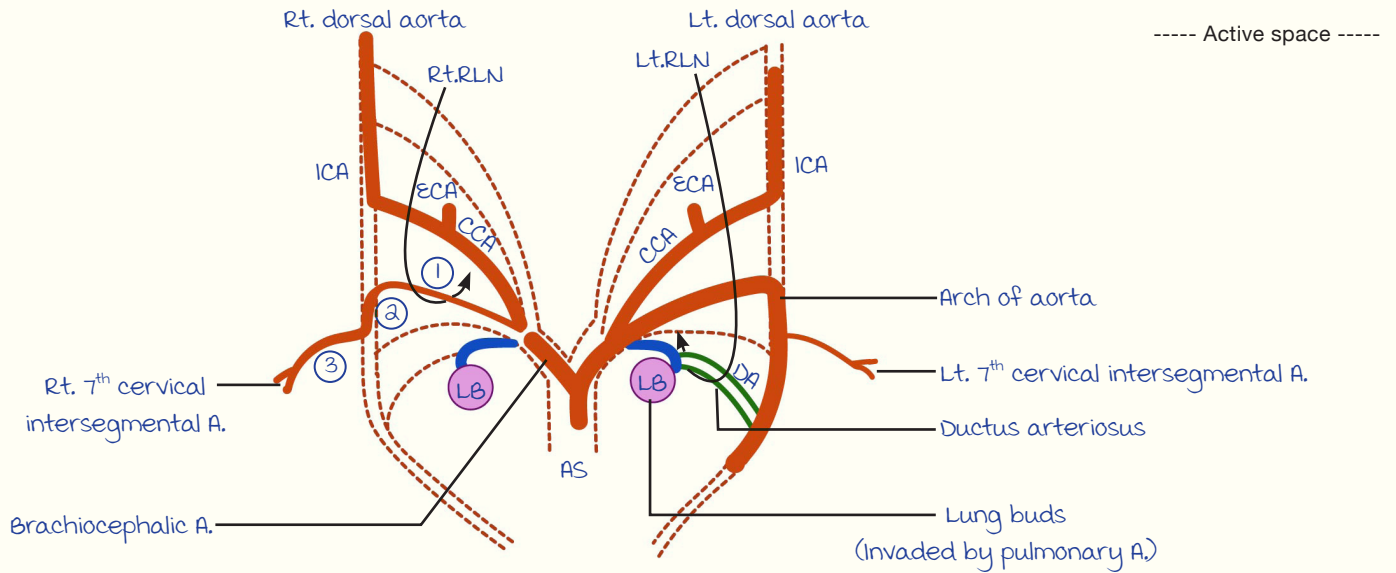
PHARYNGEAL ARCH ARTERIES

Connect the developing heart in the front to the 2 dorsal aorta.

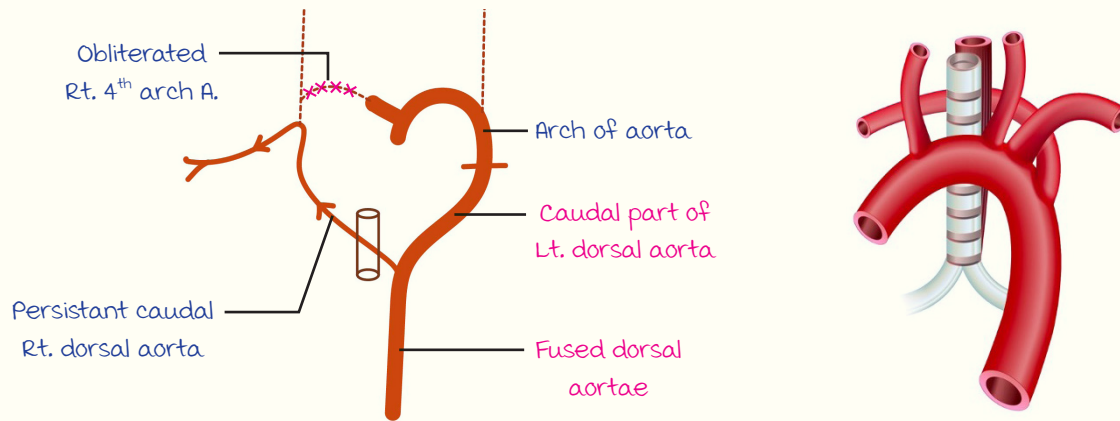
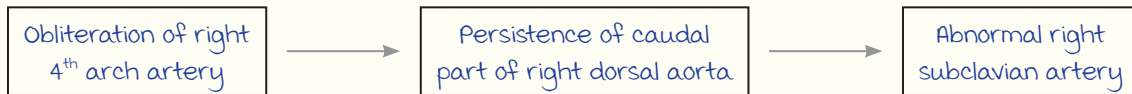
Structure		Arch artery
Arch of aorta		<ul style="list-style-type: none"> Aortic sac Left horn of aortic sac Left 4th arch artery
Brachiocephalic trunk		Right horn of aortic sac
CCA		Proximal part of 3 rd arch artery
ICA		Distal part of 3 rd arch artery
Subclavian artery	Left	Left 7 th cervical intersegmental artery
	Right	<ul style="list-style-type: none"> Right 4th arch artery Right 7th cervical intersegmental artery
Pulmonary artery		Proximal part of 6 th arch artery
Ductus arteriosus		Distal part of 6 th arch artery

Applied aspect :





Dysphagia lusoria :



Double aortic arch : Persistence of both sides.

- 4th arch arteries ξ
- Dorsal aorta.

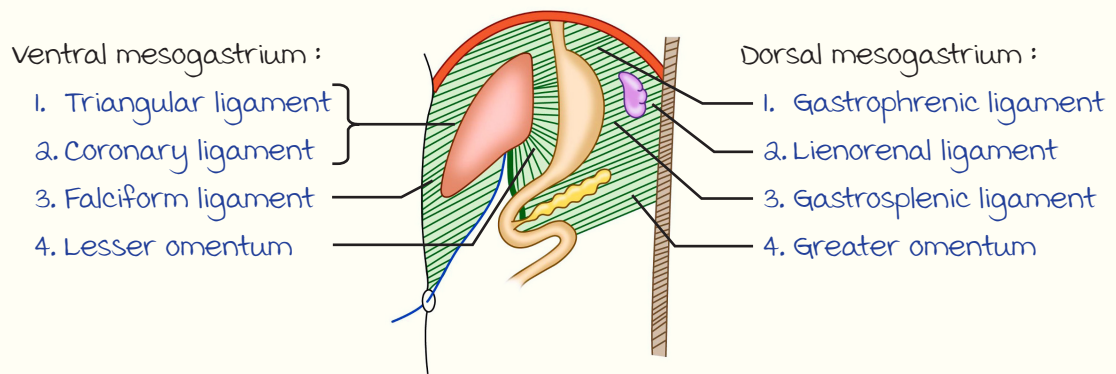
Arterial Derivatives :

Aortic arch	Derivatives
1 st arch	maxillary artery
2 nd arch	Hyoid ξ stapedial artery
3 rd arch	CCA ξ proximal ICA
4 th arch	Left : Arch of aorta
	Right : Part of right subclavian
5 th arch	Degenerates
6 th arch	Left : Proximal left pulmonary artery, distal ductus arteriosus
	Right : Right pulmonary artery

----- Active space -----

Mesogastrium & Derivatives

00:58:20

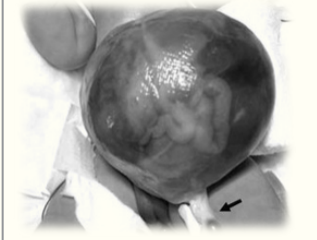

**midgut :**

Anomalies :

Anomaly	Defect in rotation	Features
<p>Non-rotation</p>	Herniation followed by arrest after 1 st rotation	<ul style="list-style-type: none"> • Small intestine on right side. • Large intestine on left side.
<p>Reverse rotation</p>	Herniation + normal 1 st rotation followed by reverse rotation	Transverse colon overlapped by SMA & small intestine
<p>mixed rotation</p>	Absent 3 rd rotation	Subpyloric caecum held by Ladd Band → Compresses small intestine
<p>Incomplete rotation</p>	Incomplete 3 rd rotation	Subhepatic caecum

Omphalocele vs gastroschisis :

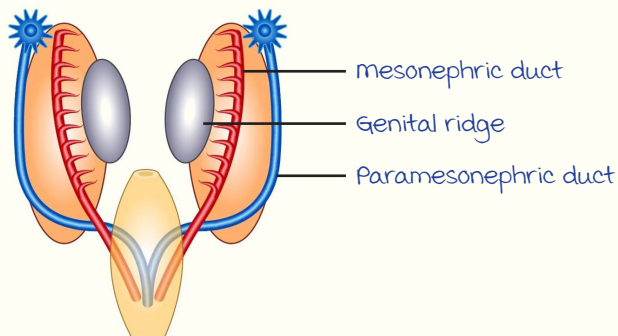
----- Active space -----

	Omphalocele	Gastroschisis
Defect	Failure of reduction of physiological hernia	<ul style="list-style-type: none"> D/t incomplete lateral folding of embryo. Re-herniation of midgut from a defect in anterior abdominal wall.
Associations	A/w multiple anomalies ↓ High mortality	Intestinal obstruction
		

Genital Duct Derivatives :

Intermediate mesoderm :

- mesonephric duct.
- Paramesonephric duct.
- Genital ridge.



males vs females :

	males	Females
mesonephric duct/ wolffian duct	<ul style="list-style-type: none"> • Posterior wall of urethra • Ureteric bud & derivatives • Trigone 	Remnant : Gartner's duct ↓ In Broad ligament
	<ul style="list-style-type: none"> • Spermatic pathway • Appendix of epididymis 	
Paramesonephric duct/ mullerian duct	Remnants : <ul style="list-style-type: none"> • Appendix of testes • Prostatic utricle 	<ul style="list-style-type: none"> • Fallopian tube • uterus • Upper vaginal wall
Genital ridge	Testes	Ovaries

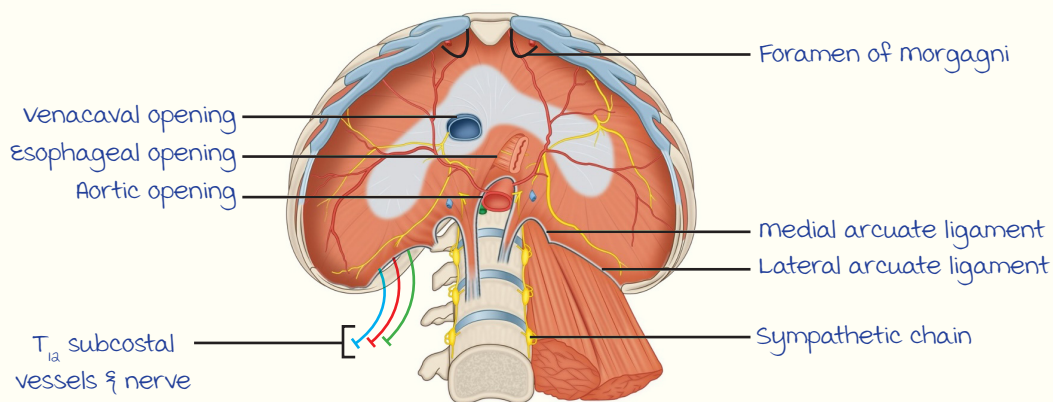
THORAX

----- Active space -----

Diaphragm

00:00:10

OPENINGS IN THE DIAPHRAGM



Inferior view of diaphragm

major Openings :

	Opening	Level	Location	Traversing structures
1	venacaval opening	T ₈	Central tendon	<ul style="list-style-type: none"> IVC Right phrenic nerve
2	Esophageal opening	T ₁₀	muscular part, surrounded by right crus	<ul style="list-style-type: none"> Oesophagus Right & left X nerve Esophageal branch of left gastric artery
3	Aortic opening	T ₁₂	B/w right & left crura of diaphragm	<ul style="list-style-type: none"> Aorta Azygos vein Hemiazygos vein Thoracic duct

minor Openings :

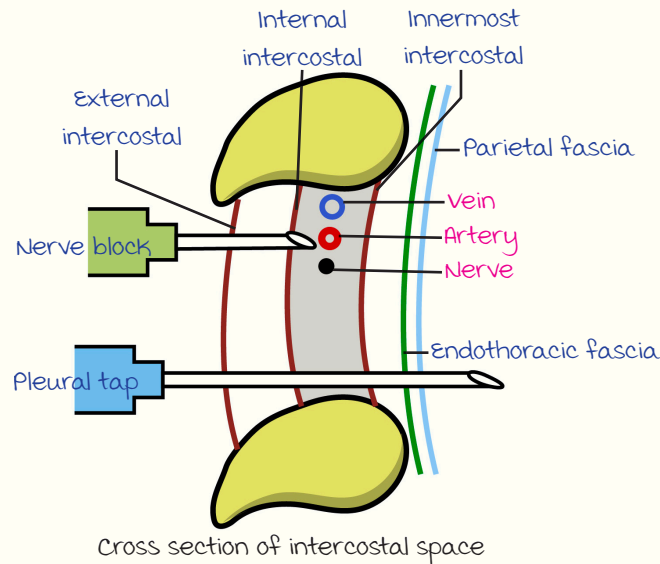
	Opening	Transversing structures
1	Foramen of Morgagni	Superior epigastric vessels
2	medial arcuate ligament	Sympathetic chain
3	Lateral arcuate ligament	T ₁₂ subcostal vein, artery & nerve

Thoracic Wall

00:07:15

----- Active space -----

NEUROVASCULAR ARRANGEMENT IN INTERCOSTAL (I/C) SPACE



Applied anatomy :

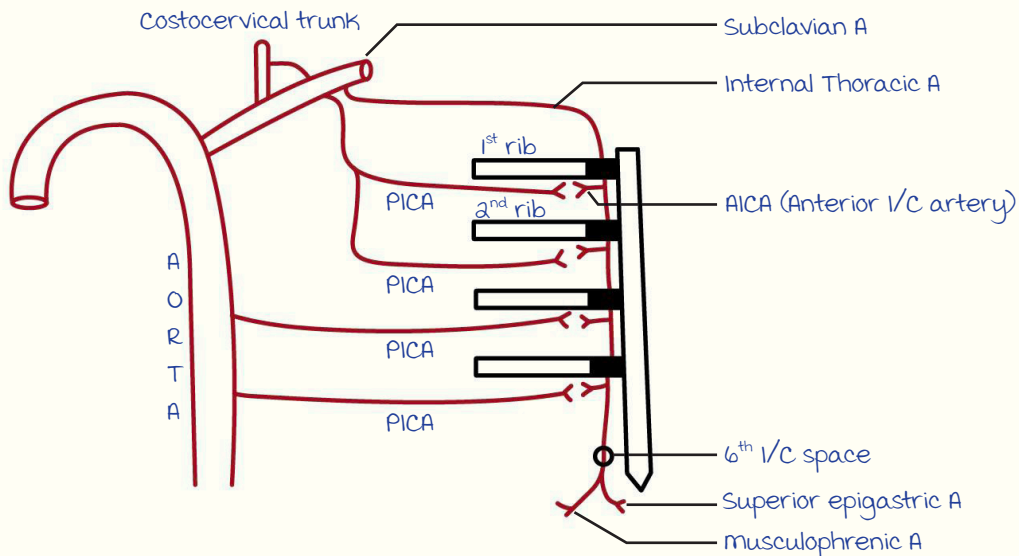
- Pleural tap : Needle inserted at **upper border of lower rib.**
- Intercostal nerve block : Administered at **lower border of upper rib.**

Note : 1st intercostal space arrangement : **Nerve** → **Artery** → **Vein.**

Intercostal Nerves :

- T₁, T₂ : Contribute to upper limb.
- T₃ - T₆ : Typical I/C nerve.
- > T₆ : Supply anterior abdominal wall.

Intercostal Arteries :



----- Active space -----

- PICA (Posterior I/C artery) :
 - 1st & 2nd I/C spaces : Branch of **costocervical trunk** of subclavian artery.
 - Remaining I/C spaces : Branch of aorta.
 - Course : Distal part of rib → Costochondral junction.
- AICA :
 - Branch of subclavian artery in all I/C spaces.
 - Course : Costochondral junction → Anastomose with PICA.

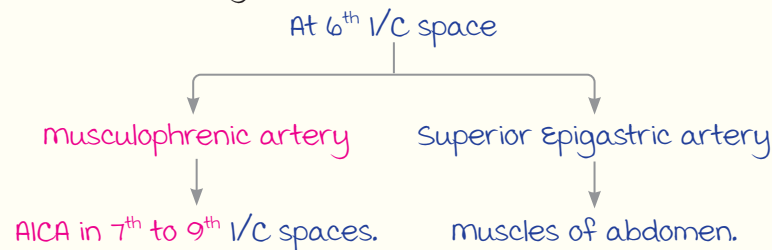
Applied anatomy :

Post-ductal coarctation of aorta3rd space onwards : Reverse blood flow from AICA → PICA → Descending aorta

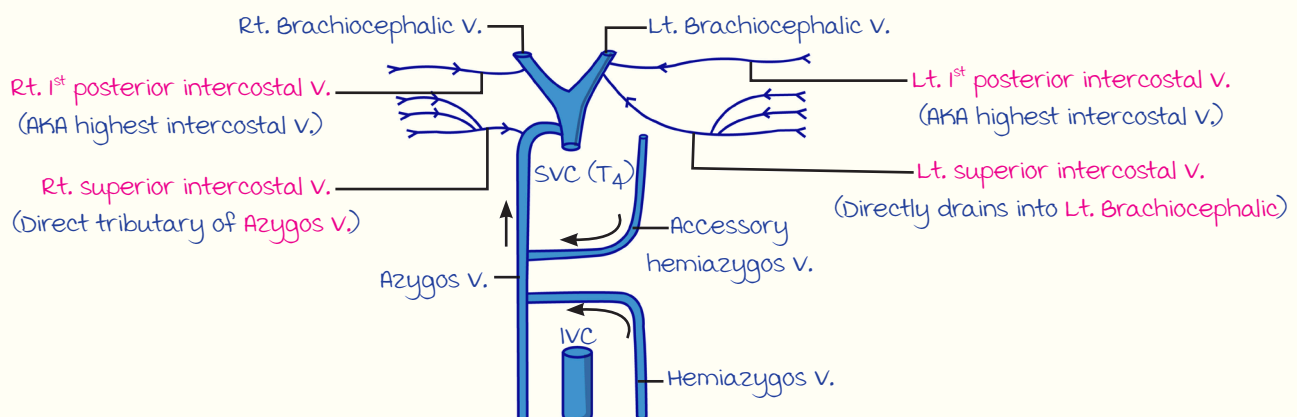
Thick, engorged, tortuous arteries

X-ray : **Rib notching.**

Fate of internal thoracic artery :



Intercostal Venous Drainage :



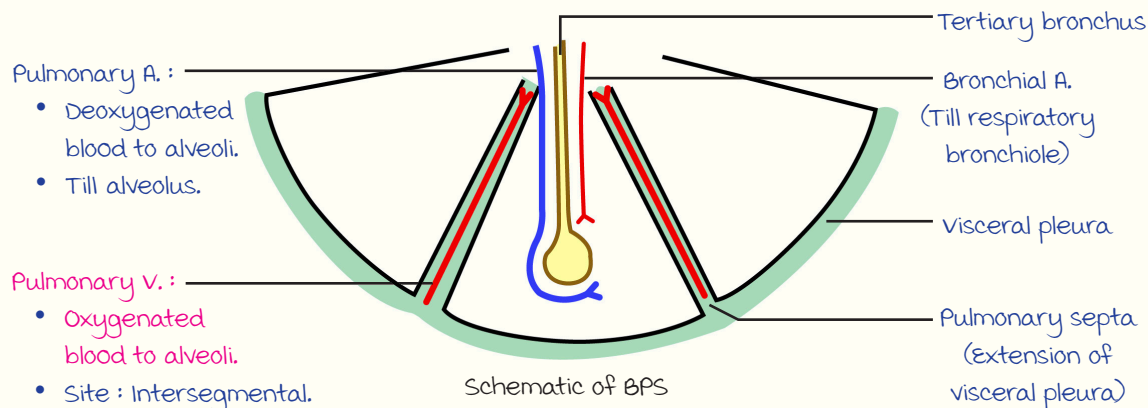
- 1st I/C vein drains $\xrightarrow{\text{Drains}}$ Brachiocephalic vein.
- Superior I/C vein (2nd to 4th) :
 - Right → Azygos vein.
 - Left → Lt. Brachiocephalic vein.

Bronchopulmonary Segment (BPS)

00:24:00

----- Active space -----

- Portion of lung aerated by 1 tertiary bronchus.
- Right lung : 10 BPS, Left lung : 9 BPS.



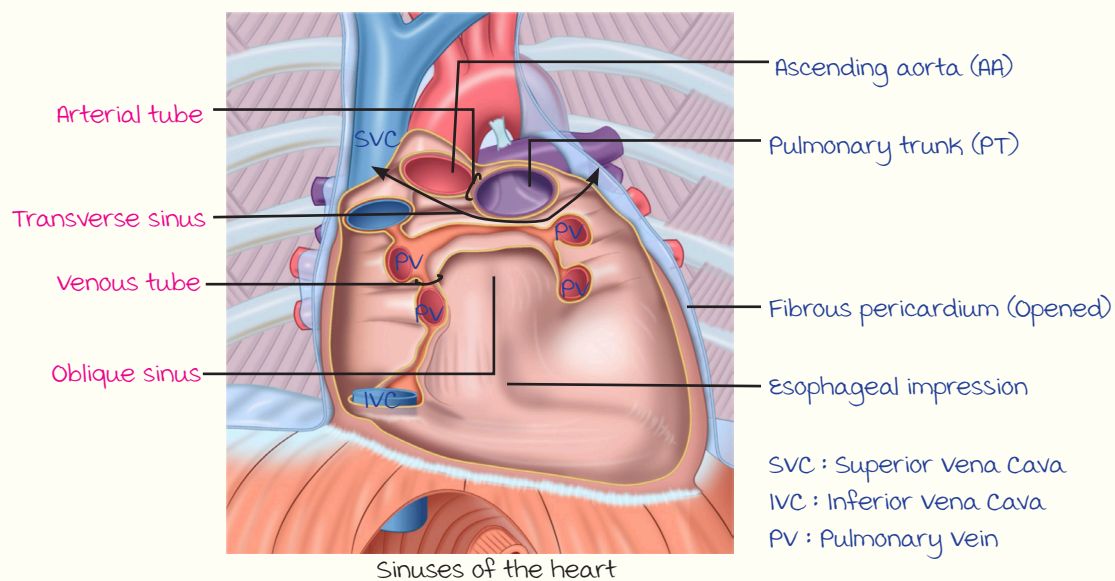
Right lung :

- Right bronchus : Shorter, wider, vertically oriented → ↑ Chance of infection. (Aspiration)
- Apical segment of upper lobe : **Least vascular** (Site for TB).
- Right superior basal of lower lobe : **most dependent BPS** in **supine** position.
- Right posterior basal segment of lower lobe : **most dependent BPS** in **sitting/standing**.

Pericardial Sinuses & Interior of Heart

00:32:28

PERICARDIAL SINUSES



Transverse sinus :

- Continuous space b/w the arterial & venous tubes.
- Surgical importance : Site for **ligation of ascending aorta & pulmonary trunk**.

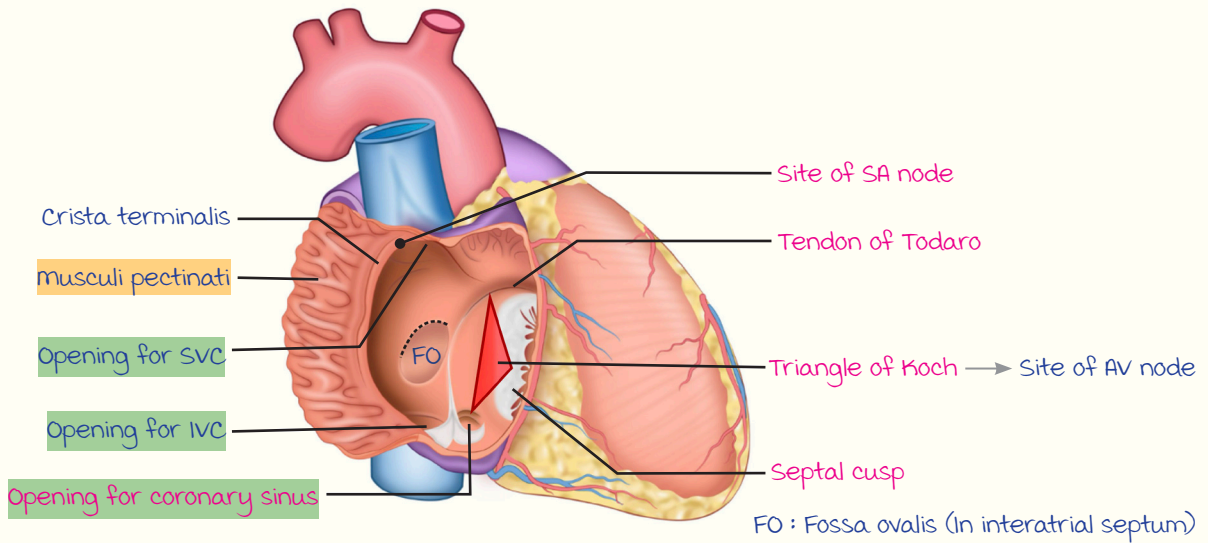
----- Active space ----- Oblique sinus :

- Cul-de-sac : Closed above.
- Space b/w the 4 pulmonary veins, behind **left atrium**.
- Allows expansion of left atrium **without compressing esophagus**.

INTERIOR OF THE HEART

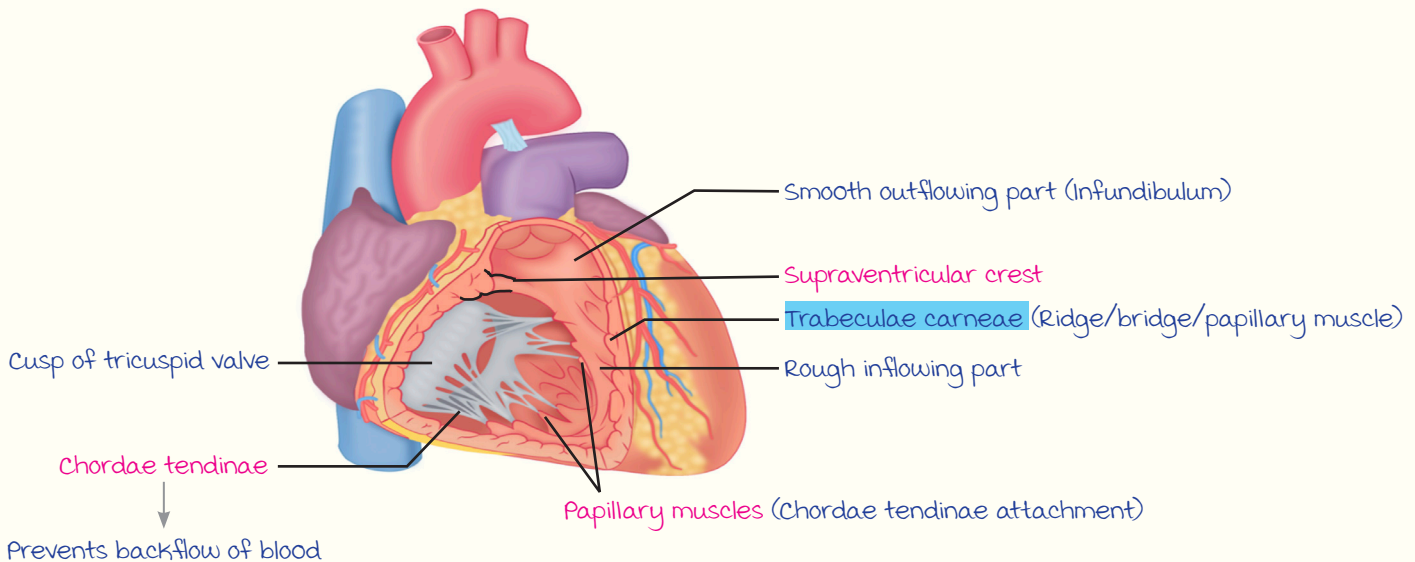
Interior of Right Atrium :

Parts { **Rough anterior wall** } Separated by crista terminalis.
 { **Smooth posterior wall** }



Interior of Right ventricle :

Parts { **Rough inflowing part** } Separated by supraventricular crest.
 { **Smooth outflowing part** }

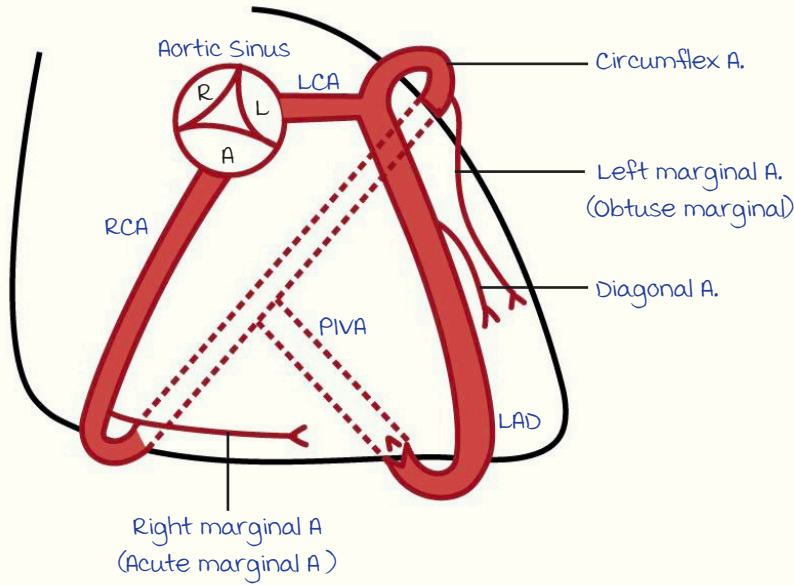


Coronary Circulation

00:45:20

----- Active space -----

Arterial Supply :



Index :

- LCA : Left coronary artery.
- RCA : Right coronary artery.
- LAD : Left anterior descending artery.
- PIVA : Posterior interventricular artery.
- Right (R), Left (L), Anterior (A) : Aortic sinus.

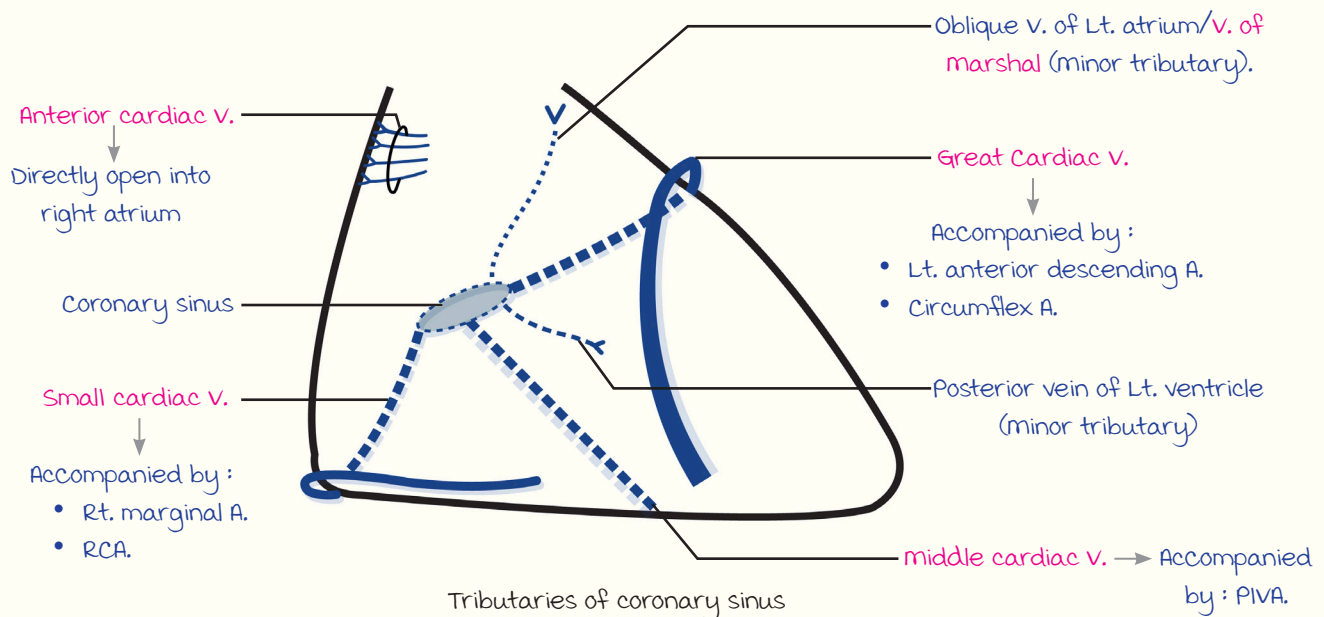
Cardiac dominance :

Based on origin of PIVA —
 RCA → Right dominance
 Circumflex artery → Left dominance

Blood supply to the conduction system :

- RCA : SA node, AV node, Bundle of His.
- LCA : RBB & LBB.

Venous Drainage :



Note : Anterior cardiac veins are not tributaries of coronary sinus.

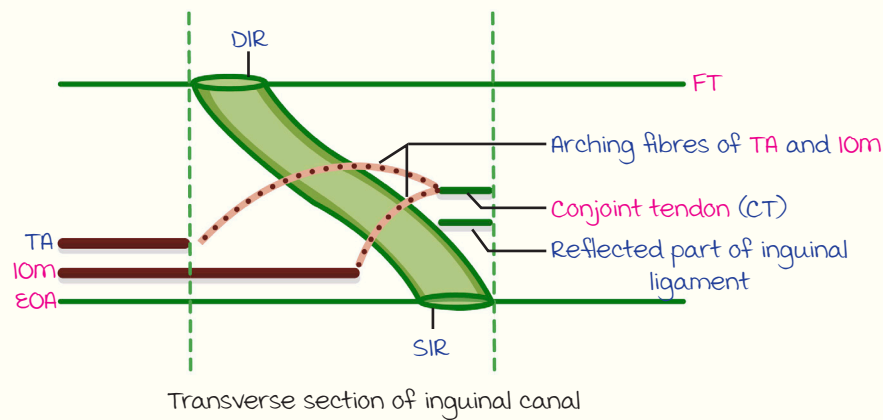
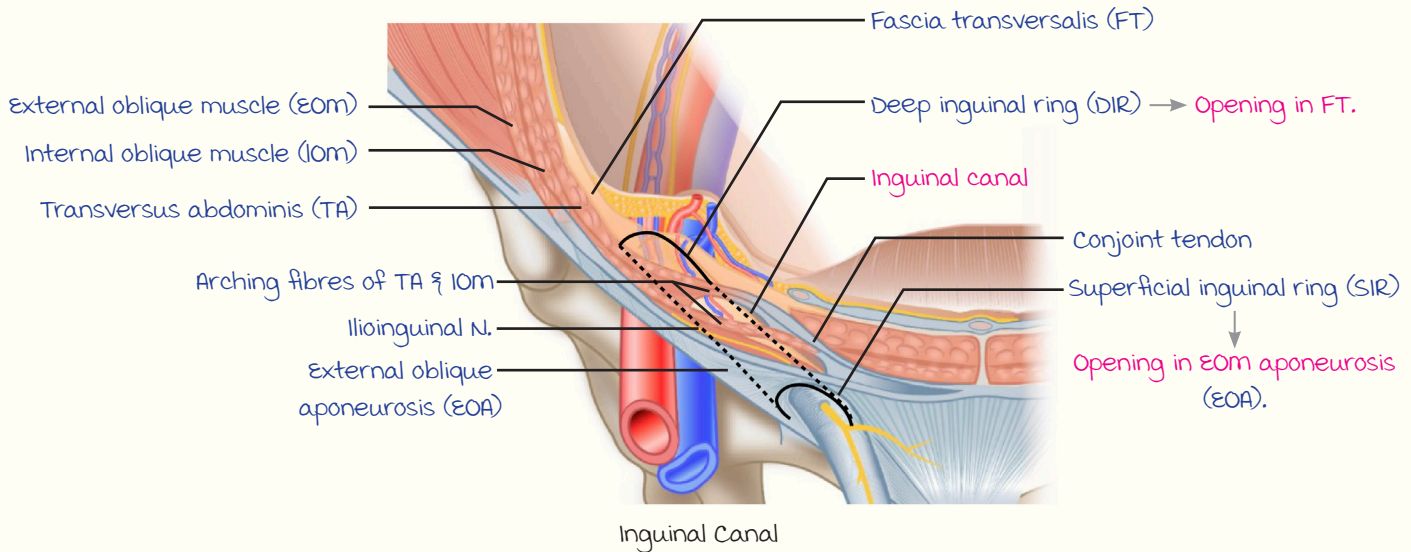
ABDOMEN

----- Active space -----

Inguinal Canal

00:00:15

Relations of Inguinal Canal :



Anterior wall :

- External oblique aponeurosis.
- Internal oblique muscle (IOM).

Posterior wall :

- Fascia transversalis (FT).
- Conjoint tendon.

Roof : Arched fibers of internal oblique & transversus abdominis (TA).

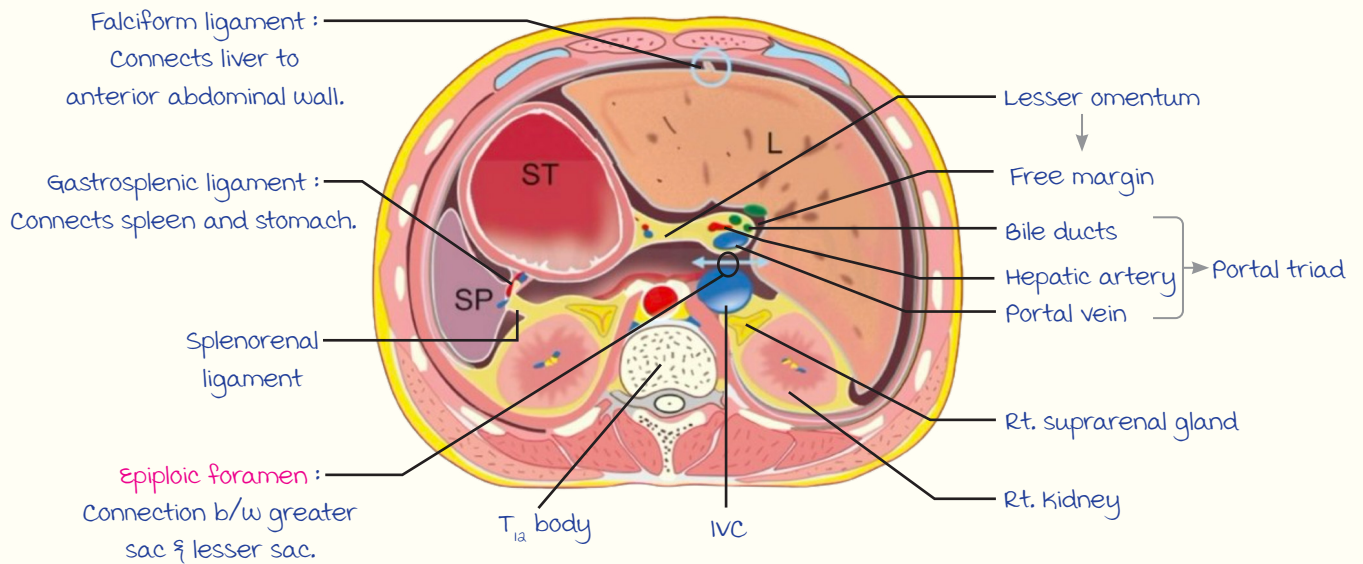
Floor :

- Inguinal ligament.
- Lacunar ligament.

Peritoneal Folds

00:06:30

----- Active space -----

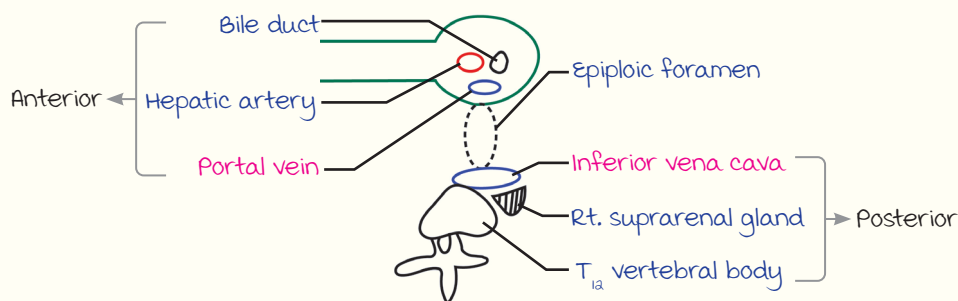


SP : Spleen L : Liver
 ST : Stomach IVC : Inferior vena cava

Contents :

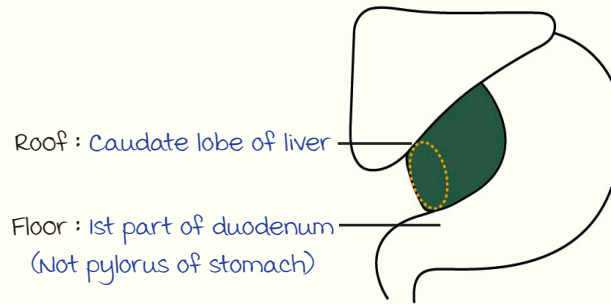
Peritoneal fold	Contents
Falciform ligament	Ligamentum teres (Remnant of left umbilical vein)
Splenorenal/lieno renal ligament	<ul style="list-style-type: none"> Splenic artery Tail of pancreas
Gastrosplenic ligament	<ul style="list-style-type: none"> Short gastric artery Left gastroepiploic artery
Lesser Omentum	<div style="display: flex; justify-content: space-around;"> <div style="text-align: left;"> <p>Free margin :</p> <ul style="list-style-type: none"> Hepatic artery Bile duct Portal vein </div> <div style="text-align: left;"> <p>Attached margin :</p> <ul style="list-style-type: none"> Left gastric artery Right gastric artery </div> </div>

Epiploic Foramen/Foramen of Winslow :

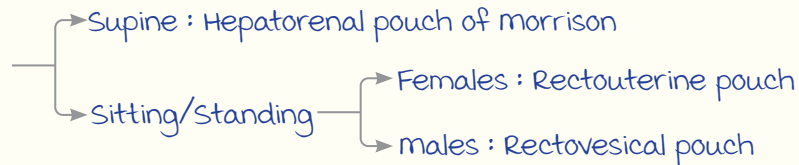


Transverse section of epiploic foramen

----- Active space -----



most dependent site of peritoneal cavity :



Phrenicocolic Ligament :

- Connects diaphragm to splenic flexure of colon.
- Responsible for spleen being directed toward right iliac fossa in splenomegaly.

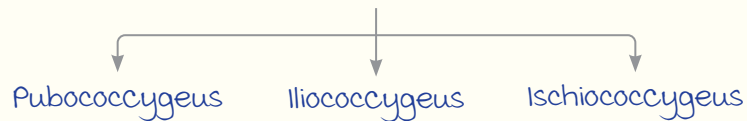
Perineum

00:17:50

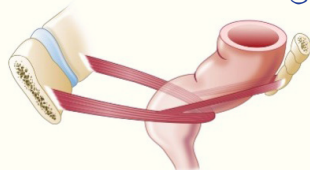
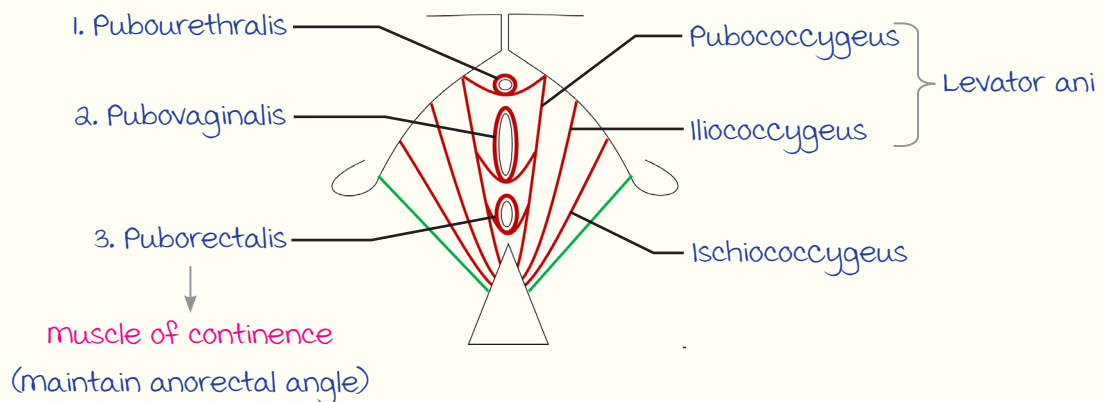
Pelvic Diaphragm :

Superior-most layer of perineum, that separates the pelvis from perineum.

Components :

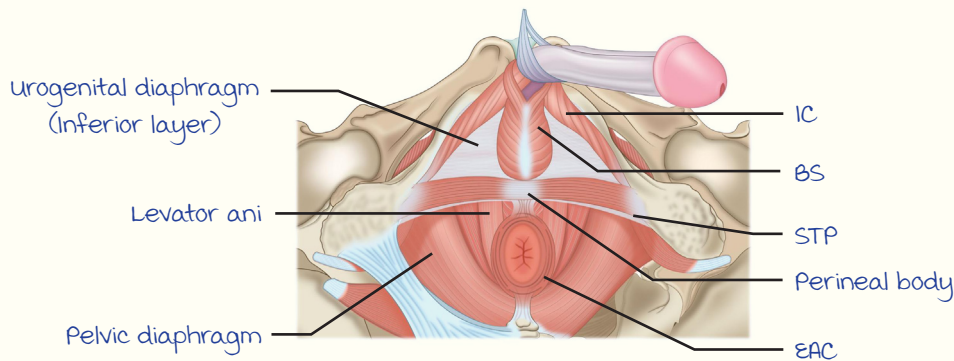
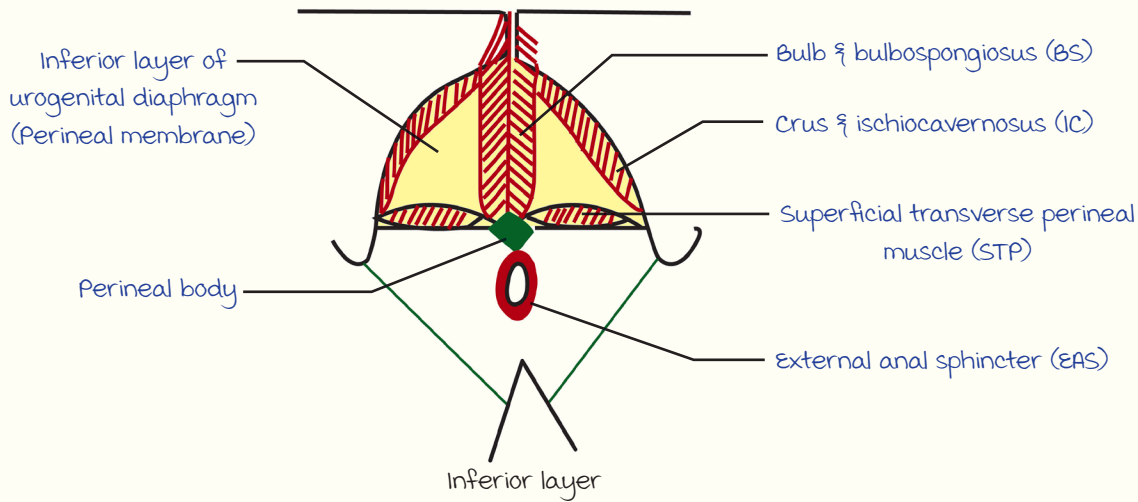


modifications of pubococcygeus :



Urogenital Diaphragm :

----- Active space -----

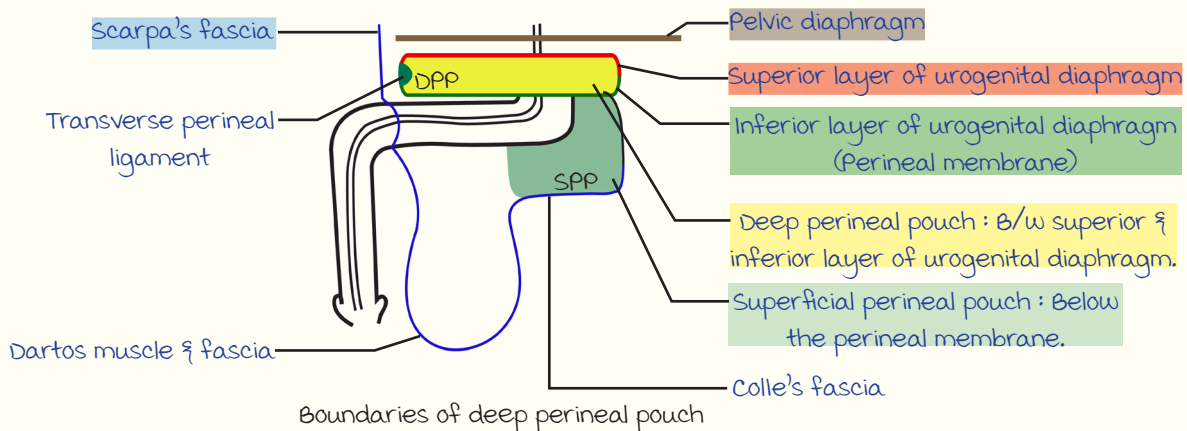


Perineal Body :

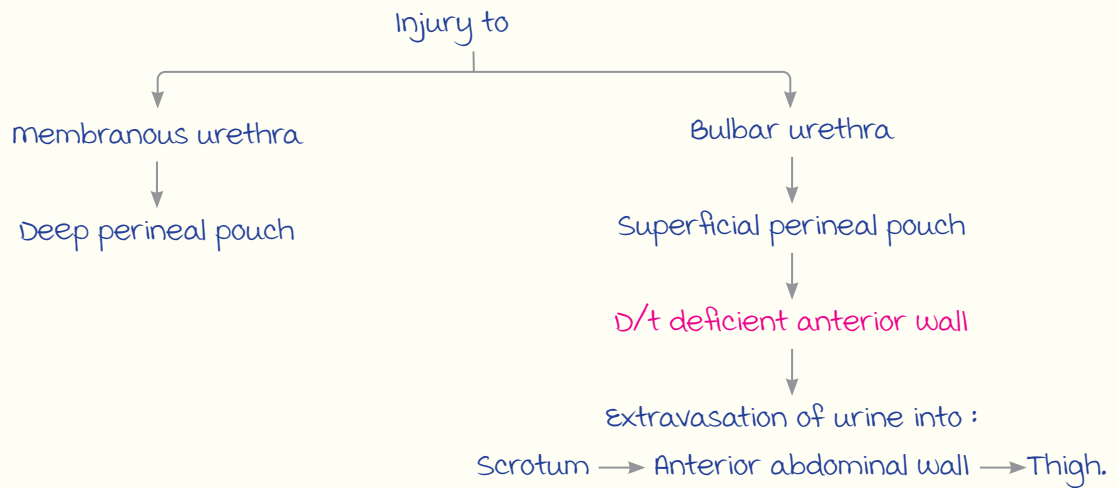
- | | |
|---|--|
| <p>Paired (4) :</p> <ol style="list-style-type: none"> 1. Superficial transverse perinei. 2. Deep transverse perinei. 3. Bulbospongiosus. 4. Levator ani. | <p>Unpaired (2) :</p> <ol style="list-style-type: none"> 1. External anal sphincter. 2. Longitudinal muscle of anal canal. |
|---|--|

Note : Ischiocavernosus is not a part of perineal body.

PERINEAL POUCH



----- Active space ----- Extravasation of urine :



Contents :

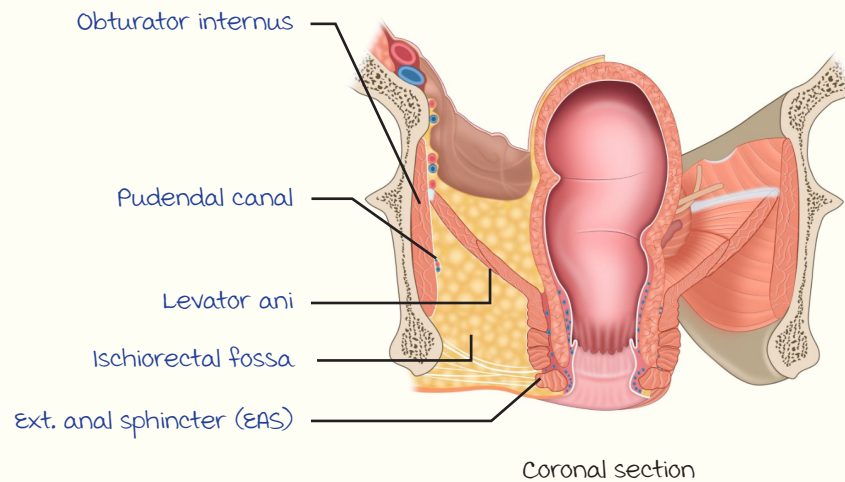
Deep perineal pouch :

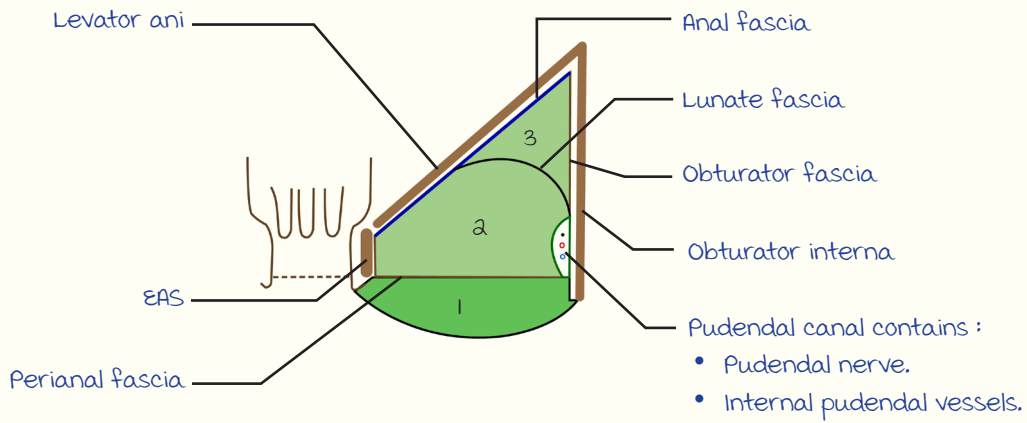
- membranous urethra.
- External urethral sphincter.
- Bulbourethral (Cowper's) gland (male).

Superficial perineal pouch :

- Bulb of penis & bulbospongiosus.
- Crus of penis & ischiocavernosus.
- Superficial transverse perinei & other muscles below perineal membrane.
- Bartholin's gland (Females).

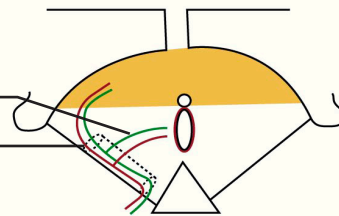
ISCHIORECTAL FOSSA/ISCHIOANAL FOSSA





Contents :

1. Fat
2. Inferior rectal nerves & vessels
3. Pudendal canal & its contents



Applied anatomy :

Drainage of Ischioanal fossa abscess :

- Risk of injury to inferior rectal nerves & vessels (D/t horizontal course)
- Horseshoe recess : Communication of both IRF → Spread of IRF abscess to the C/L side.




















HEAD, NECK AND FACE

----- Active space -----

Cranial Nerve Nuclei & Columns

00:00:10

CRANIAL NERVE COLUMN

	Efferent			Afferent		
	GSE	SVE	GVE	GVA & SVA	GSA	SSA
Supply	Extraocular & tongue muscles	Pharyngeal arch muscles (mastication, facial expression, palate, pharynx, larynx)	Smooth muscles & glands	General sensations from viscera + taste	General sensations from body wall	Vision, olfaction, hearing & balance
midbrain	 III (Superior colliculus)  IV (Inferior colliculus)		 Edinger Westphal		mesencephalic	CN I & II : No nuclei
Pons	 VI (Facial colliculus)	 V ₃  VII	 SSN  ISN		 Principal sensory	CN VIII :  V  C
medulla	 XII	 IX X XI Nucleus ambiguus	 Dorsal nucleus of vagus	 NTS	 Spinal nucleus  Trigeminal nucleus	 V  C Vestibulo-cochlear nucleus

Index :

GSE : General somatic efferent.

SVE : Special visceral efferent.

GVE : General visceral efferent.

GVA : General visceral afferent.

SVA : Somatic visceral afferent.

GSA : General somatic afferent.

SSA : Special somatic afferent.

SSN : Superior salivatory nucleus.

ISN : Inferior salivatory nucleus.


NTS : Nucleus tractus solitarius.

Parasympathetic cranial nerves :

- III : GSE, GVE.
- VII
- IX } SVE, GVE, GVA, SVA, GSA.
- X }

General somatic afferent : Trigeminal nuclei → 3 parts.

----- Active space -----











Part	Function	Location
1. mesencephalic	Proprioception : • mediates jaw reflex • Only site in CNS containing pseudo-unipolar neurons	midbrain
2. Principal sensory	Touch & pressure	Pons
3. Spinal nucleus	Pain & temperature	medulla

Note :

Any nerve carrying general sensations from body wall can enter the trigeminal nucleus. Eg :





- Arnold's nerve.
- Glossopharyngeal nerve (Proprioception from stylopharyngeus).

Parasympathetic Ganglion :

GVE (Parasympathetic column)	Ganglion	Supply
midbrain :  Edinger Westphal	 Ciliary ganglion	Sphincter pupillae & ciliaris muscle
Pons :  SSN	 Pterygopalatine ganglion  Submandibular ganglion	Lacrimal gland Submandibular & sublingual gland
 ISN	 Otic ganglion	Parotid gland
medulla :  Dorsal nucleus of X		Smooth muscles & glands of thorax & abdomen

----- Active space ----- Parasympathetic outflow : Cranio-sacral
 ↓
 CN III, VII, IX, X. S2, S3, S4.
 Sympathetic outflow : Thoracolumbar → T1 to L2.

RULE OF 17

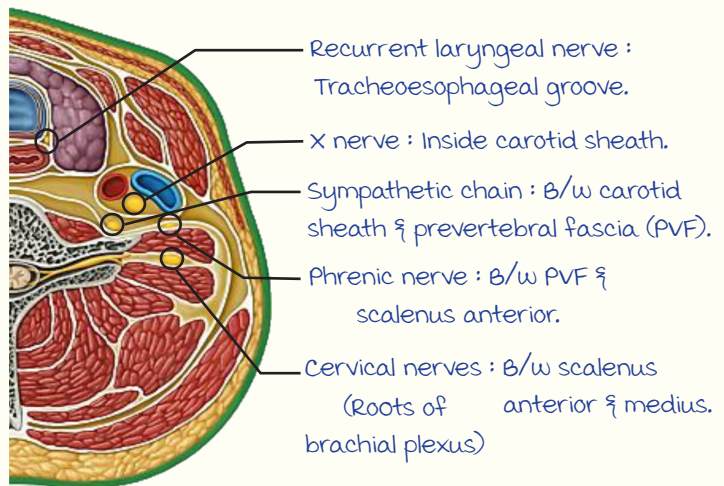
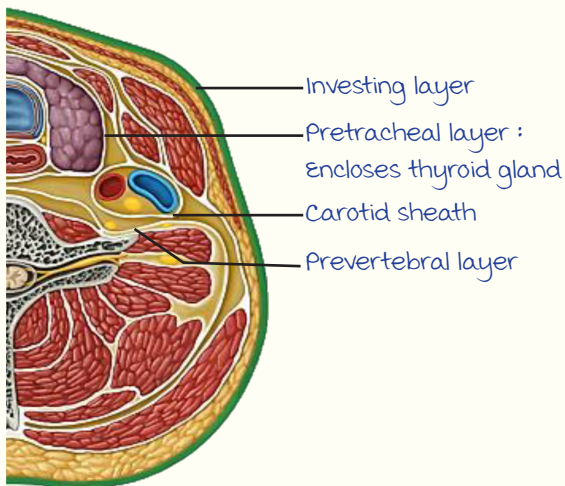
Lesion : X + VII	Lesion : XII + V
Deviation : Contralateral deviation	Deviation : Ipsilateral deviation
 <ul style="list-style-type: none"> • Right X nerve lesion ↓ Deviation of uvula to the left. 	 <ul style="list-style-type: none"> • Left XII nerve lesion ↓ On protrusion, deviation of tongue to the left.
 <ul style="list-style-type: none"> • Right VII nerve lesion ↓ Deviation of facial muscles to the left. 	 <ul style="list-style-type: none"> • Left V nerve lesion ↓ Deviation of jaw to the left.

Deep Cervical Fascia

00:29:11

Layers :

Nerves Enclosed :



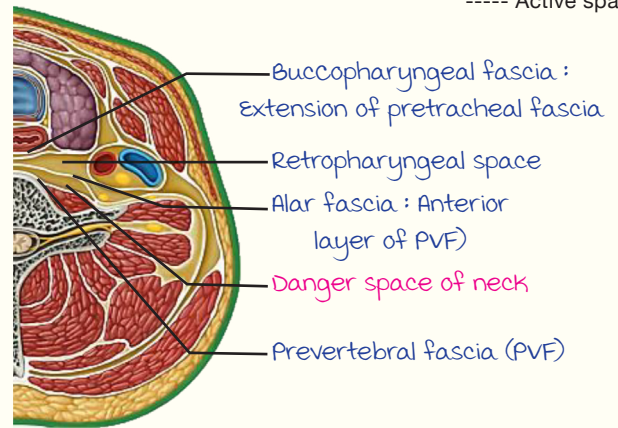
Transverse section of neck

Danger Space of Neck :

- Between alar fascia & prevertebral fascia.
- Open below till diaphragm.

Infection/abscess can descend down to posterior mediastinum

Dysphagia & dyspnea.



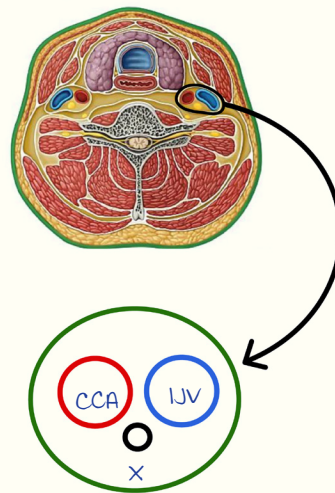
Carotid Sheath :

Receives contribution from

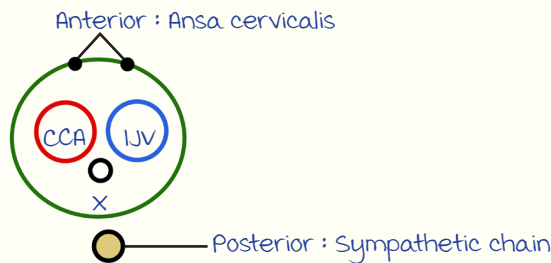
- Investing layer.
- Pretracheal layer.
- Prevertebral layer.

Contents :

1. Common Carotid Artery (CCA).
2. Internal Carotid Artery (ICA).
3. Internal Jugular vein (IJV).
4. X nerve.
5. Traversed by IX, XI, XII nerve in the upper part.



Relations :



Investing Layer :

Rule of 2 :

- 2 muscles : Sternocleidomastoid & trapezius.
- 2 glands : Parotid & submandibular.
- 2 ligaments : Stylomandibular & sphenomandibular.
- 2 spaces : Suprasternal & supraclavicular.
- 2 pulleys : Digastric & omohyoid.

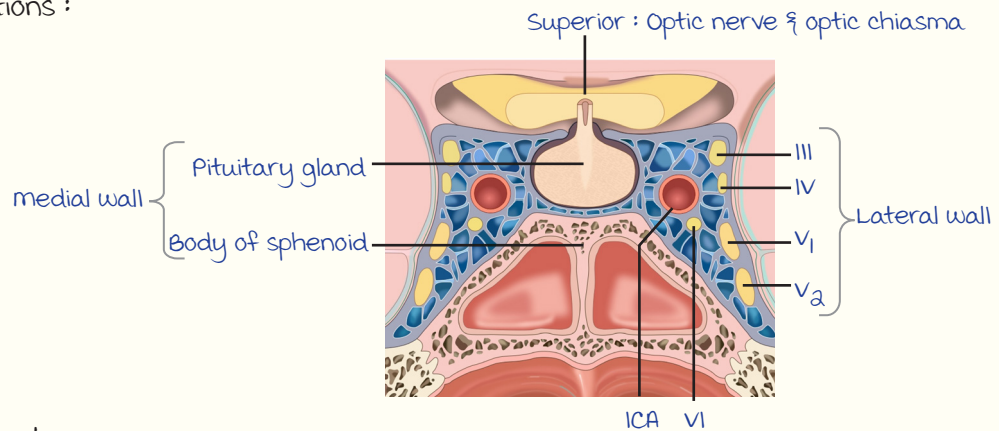
----- Active space -----

Cavernous Sinus & Muscles of Mastication

00:39:45

Cavernous Sinus :

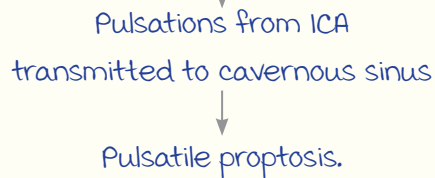
Relations :



Contents :

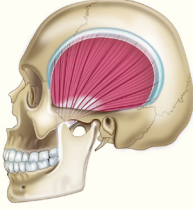
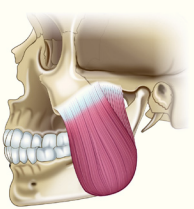
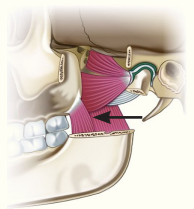
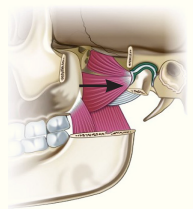
- Internal Carotid artery (ICA).
- **CN VI** (Affected in cavernous sinus thrombosis).

Applied anatomy : Rupture of ICA → Carotidocavernous fistula



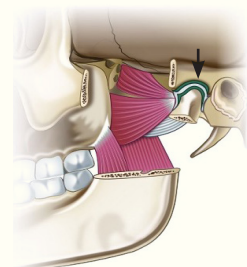
muscles of mastication :

Insertion : mandible.

muscle	Temporalis	masseter	medial pterygoid	Lateral pterygoid
Function	 Elevation & retraction	 Elevation (Strongest muscle of mastication)	 Elevation (main), Protraction	 Protraction & depression

Note :

Articular disc of TMJ (Temporomandibular joint) : Extension of tendon of lateral pterygoid.



Triangles of Neck

00:47:37

----- Active space -----

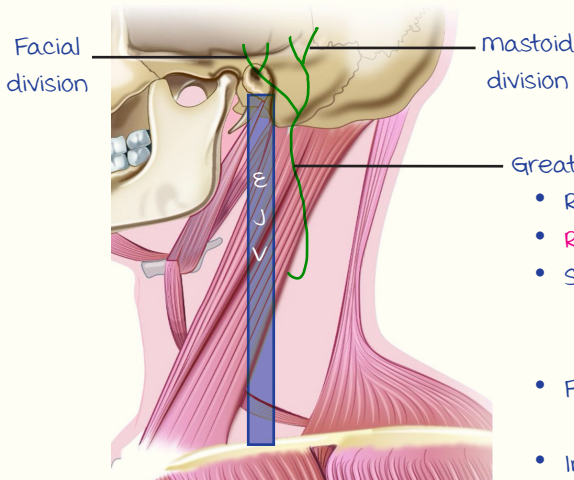
Digastric triangle : Submandibular gland

↓
Closely related to **lingual nerve** : m/c nerve injured during submandibular/Wharton's duct Sx.

Posterior Triangle of Neck :

Contents :

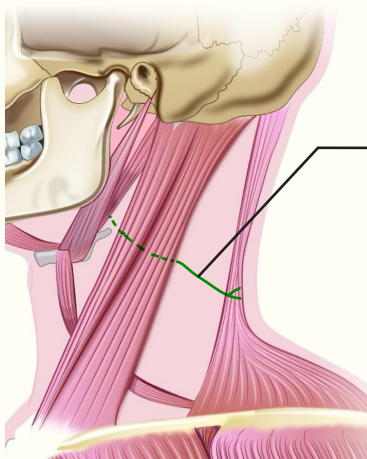
- Great auricular nerve.
- Spinal accessory nerve.



- Great Auricular Nerve (GAN) :
- Root value : C₂-C₃.
 - **Runs with EJV.**
 - Supplies :
 - Ear lobule.
 - Skin at angle of mandible & parotid region.
 - Frey's syndrome : Auriculotemporal nerve (ATN) communicates to GAN (m/c).
 - Injured in parotid Sx → **Sensory loss in shaving area.**

Note : ATN injury during parotid Sx

↓
Sensory loss on upper 2/3rd of auricle & temple.



- Spinal accessory nerve :
- Supplies SCM & trapezius.
 - Runs b/w investing layer & prevertebral layer.
 - Injury in posterior triangle → **SCM spared.**
 - Trapezius affected → Difficulty in :
 - Shrugging of shoulder.
 - Retraction of scapula.
 - Overhead abduction
 - Winging of scapula.

----- Active space -----

Skull Foramina & Pterion

00:55:40

Foramen Lacerum :

Formation : Space left in b/w the following bones.

1. Sphenoid bone.
2. Apex of petrous temporal bone.
3. Basilar part of occipital bone.

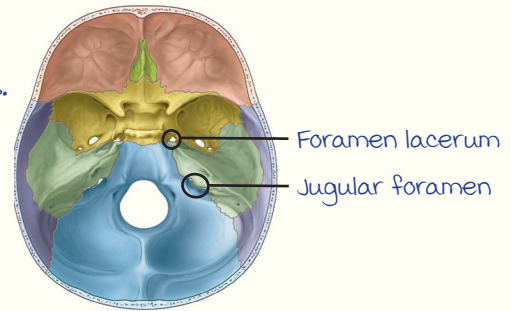
Contents :

True content :

1. meningeal branches of ascending pharyngeal artery.
2. Emissary veins : Connects cavernous sinus to pterygoid venous plexus.

Partial content :

1. ICA.
2. Sympathetic plexus.
3. Deep petrosal nerve.
4. Greater petrosal nerve. } vidian nerve.

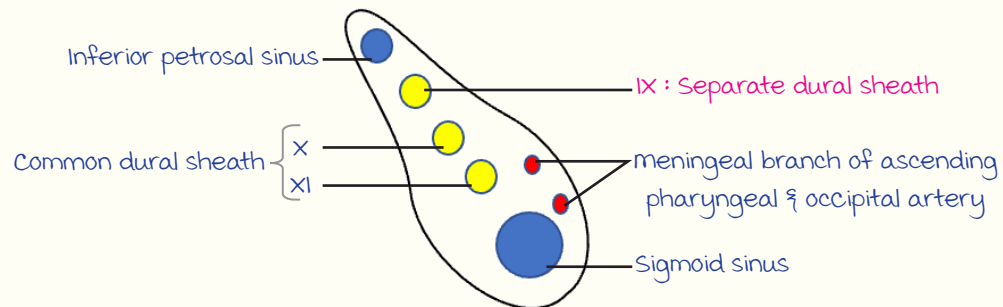
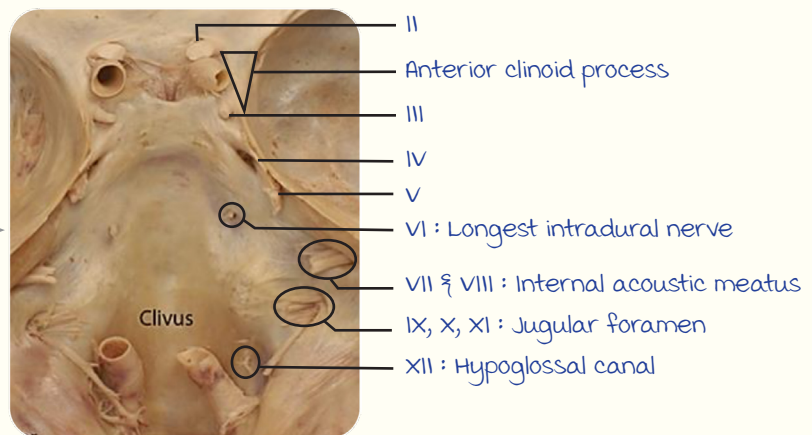
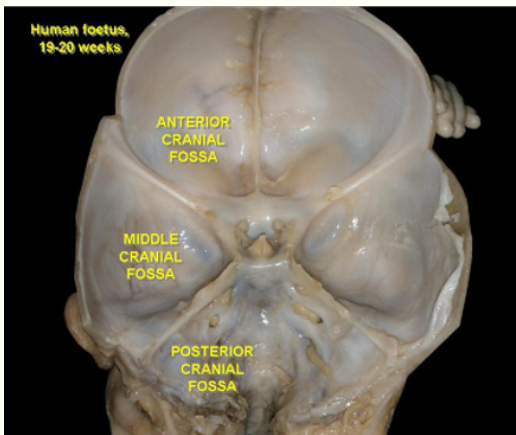


Skull foramina

Jugular Foramen :

B/w petrous temporal & occipital bone.

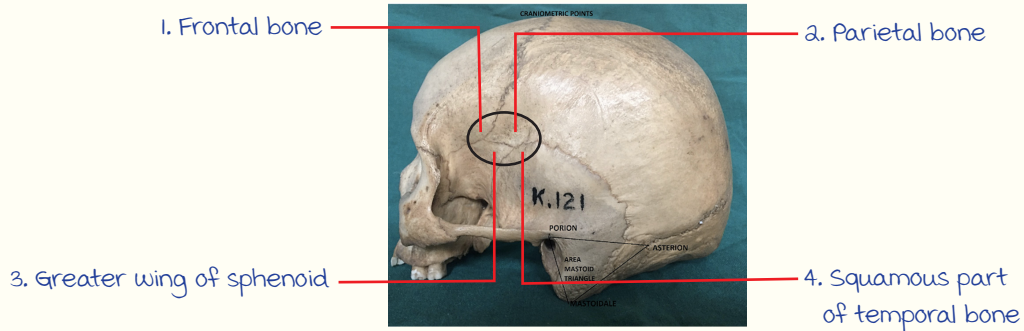
Contents :

**Identification of Cranial Nerves With Dura mater Intact :**

PTERION

Formation :

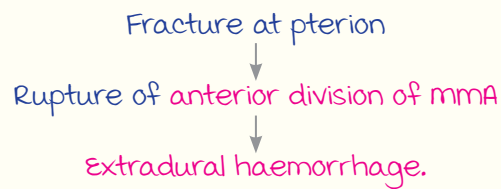
meeting point of 4 bones :



Structures Lying Deep to Pterion :

1. Anterior division of middle meningeal artery (MMA).
2. middle cerebral vessels.
3. Sylvian fissure.
4. Insula.
5. Broca's motor speech area (On the left).
6. Lesser wing of sphenoid.

Applied anatomy :



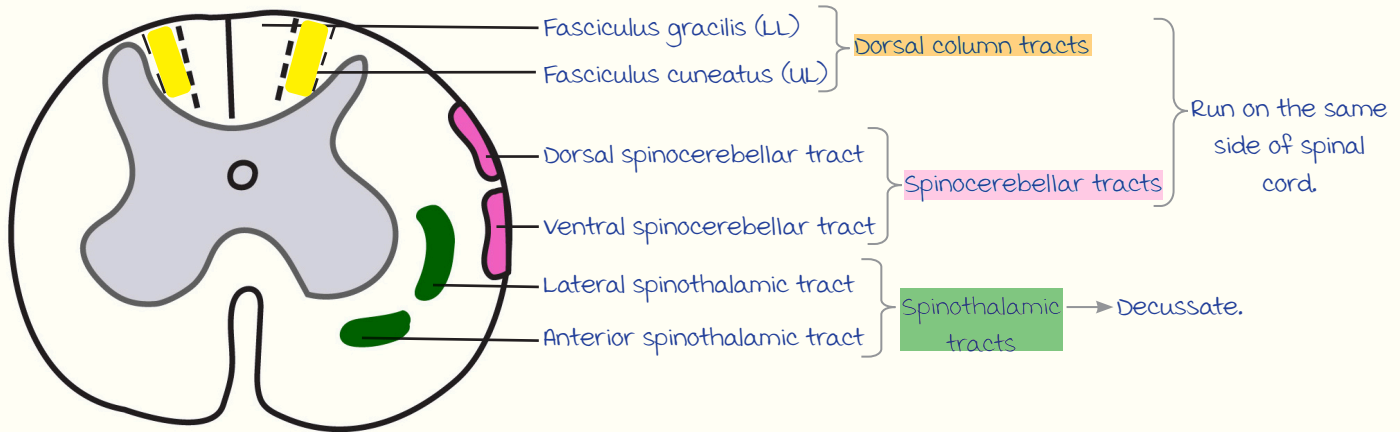
NEUROANATOMY : PART 1

----- Active space -----

Spinal Cord Tracts

00:00:10

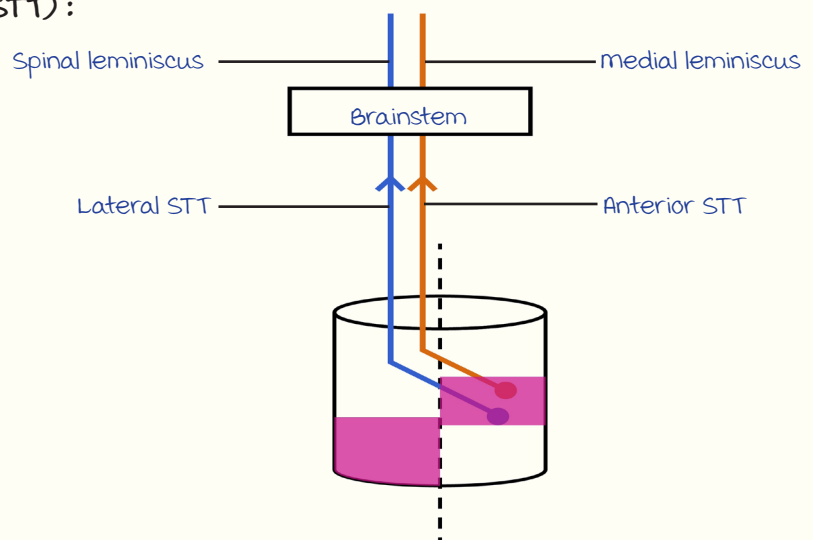
ASCENDING TRACTS



Tract	Function
Fasciculus gracilis (Lower Limb)	<ul style="list-style-type: none"> Conscious proprioception Fine touch Vibration Stereognosis minor : Pressure
Fasciculus cuneatus (Upper Limb)	
Dorsal spinocerebellar tract	unconscious proprioception
Ventral spinocerebellar tract	
Lateral spinothalamic tract	Pain & temperature
Anterior spinothalamic tract	Crude touch & pressure

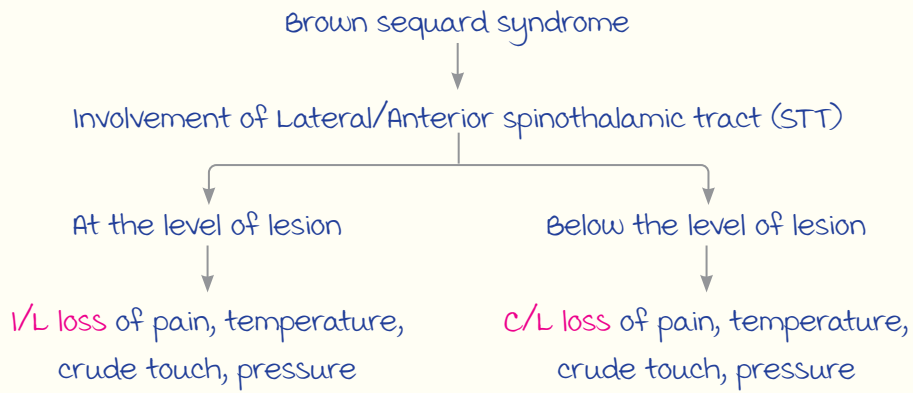
Spinothalamic Tract (STT) :

Level of injury	Loss of function
Brainstem	c/L
Spinal cord	c/L
At the level of entry of tract	1/L

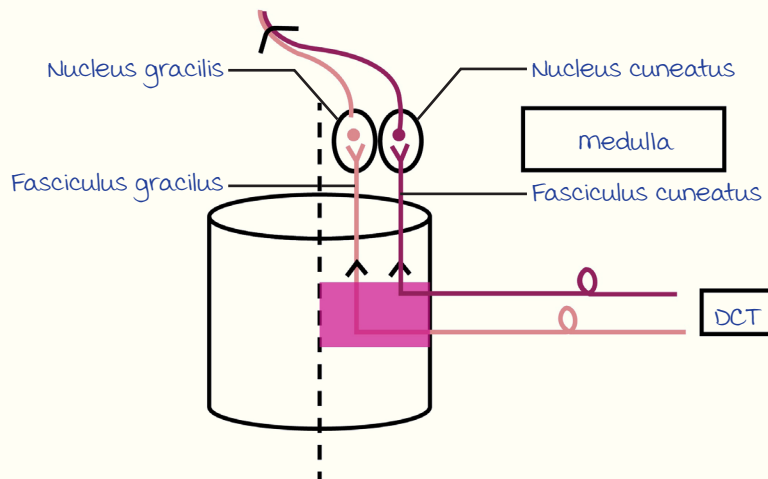


Applied aspect :

----- Active space -----

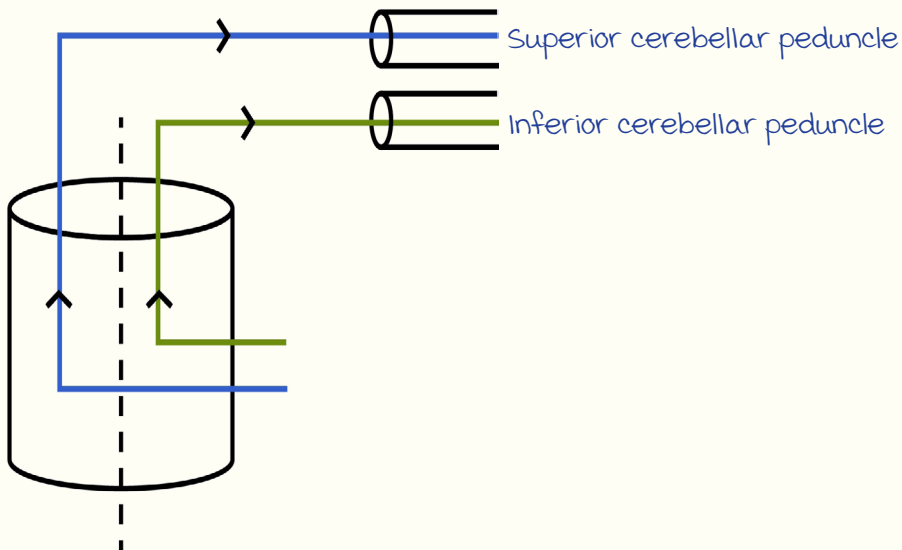


Dorsal Column Tract (DCT) :



DCT injury → V/L loss conscious proprioception, vibration, stereognosis, fine touch.

Spinocerebellar Tract :



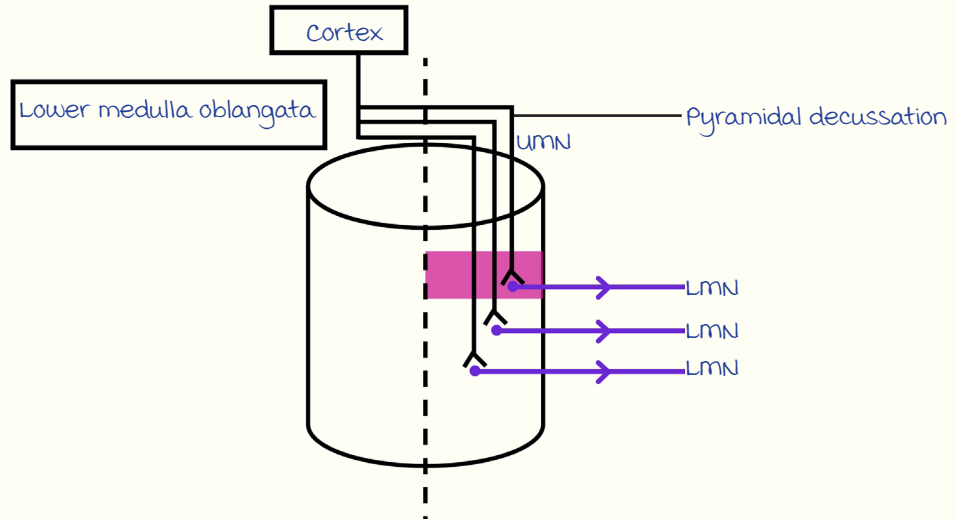
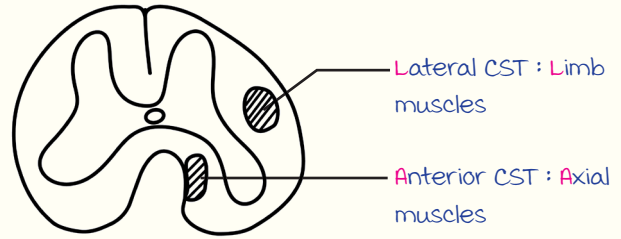
Injury to spinocerebellar tract → V/L ataxia, loss of unconscious proprioception.

----- Active space -----

DESCENDING TRACTS

Corticospinal Tract (CST)/Pyramidal Tract :

Responsible for voluntary movements



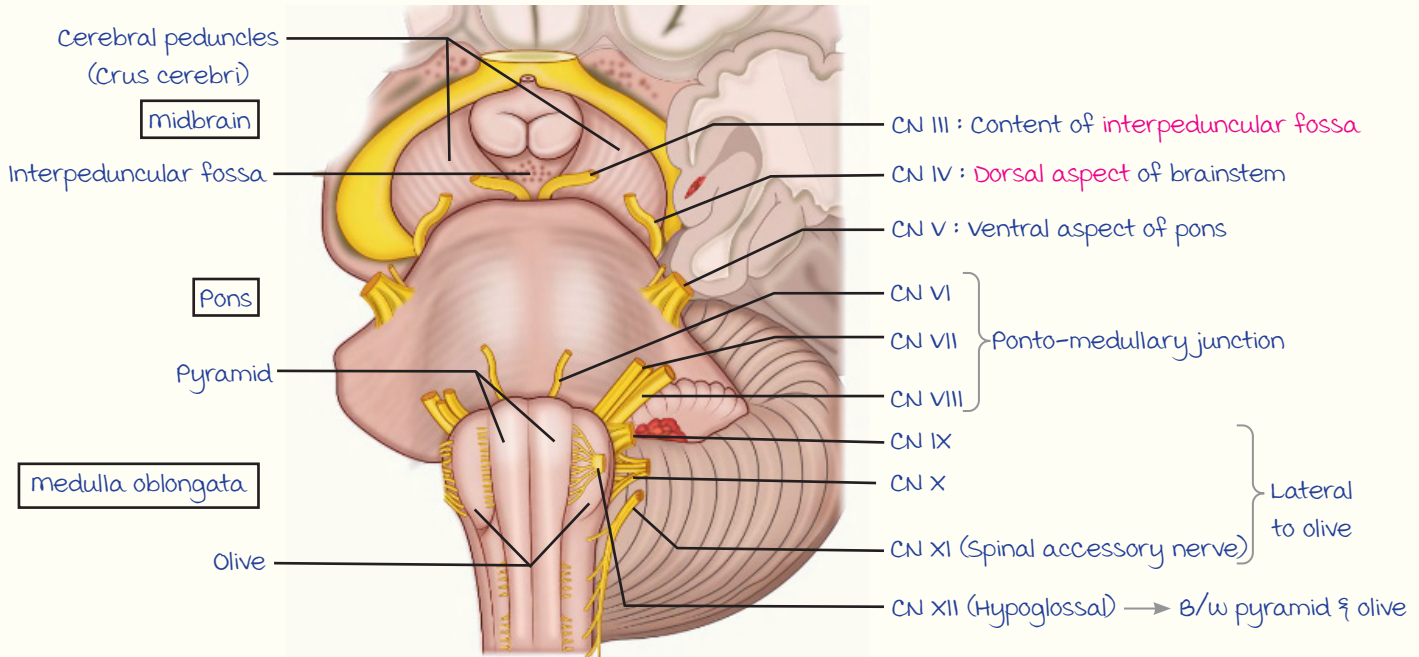
Applied aspect :

- Brown-Segard syndrome
- At the level of lesion → 1/2 flaccid paralysis
 - Below the level of lesion → 1/2 spastic paralysis

Brainstem

00:22:40

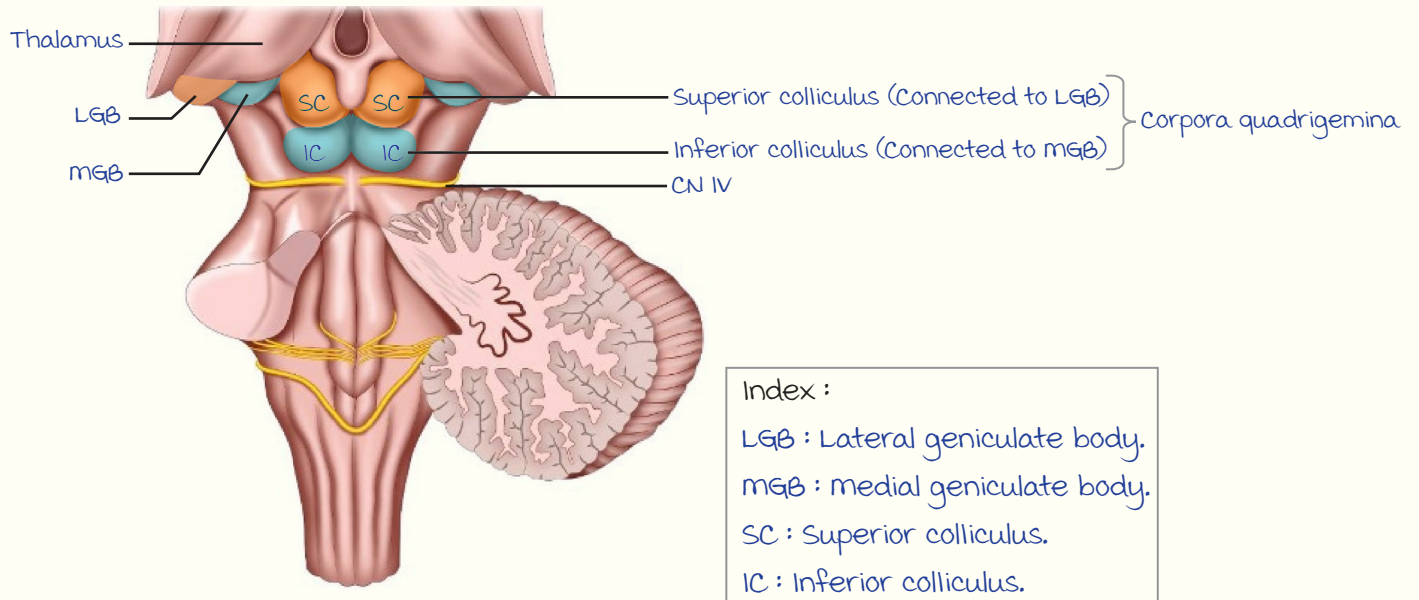
VENTRAL ASPECT OF BRAINSTEM



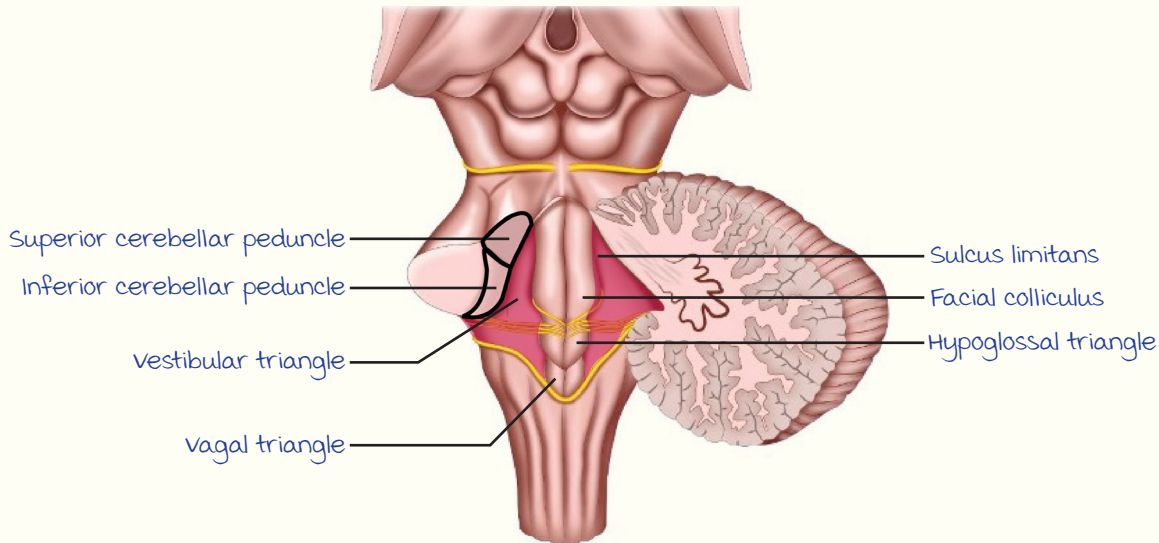
Cranial nerves emerging from ventral aspect of brainstem

DORSAL ASPECT OF BRAINSTEM

----- Active space -----



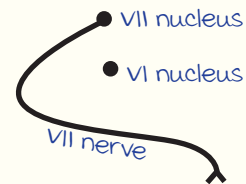
Floor Of IV ventricle/Rhomboid Fossa :



Facial colliculus :

- Elevation produced by the internal genu of facial nerve around the abducent nucleus.
- Injury to facial colliculus : Affects VII nerve > VI nucleus

↓
 muscles of facial expression > Lateral rectus

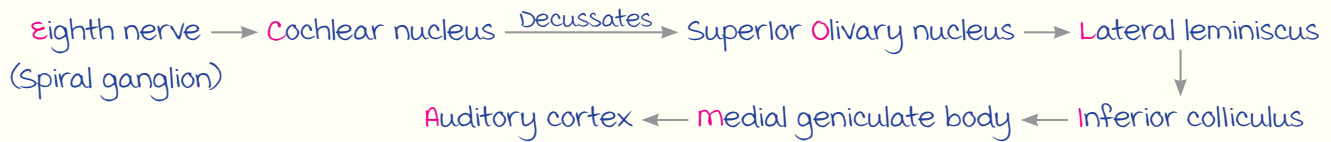
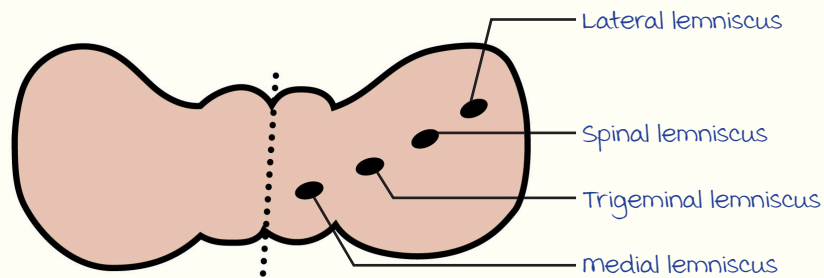


Cranial nerve nuclei present deep to IV ventricle : VI, VIII, X, XII.

----- Active space -----

Leminisci

00:38:24

Auditory Pathway :mnemonic : **E COLI MA.****Arrangement In The Brainstem :****Injury :**

Leminiscus	Clinical features
Lateral lemniscus	C/L hearing loss
Spinal lemniscus	C/L loss of pain & temperature (Below face)
Trigeminal lemniscus	C/L loss of sensations from face
medial lemniscus (Anterior STT & DCT)	C/L loss of : <ul style="list-style-type: none"> • Touch • Conscious proprioception • Pressure • Vibration • Stereognosis

Examples :

Features	Probable Diagnosis
Abducens/Facial nerve palsy + C/L loss of sensations	Pontine syndrome with involvement of medial lemniscus
Tongue paralysis + C/L loss of conscious proprioception, vibration	medial medullary syndrome
Dysphagia, dysarthria (IX, X, XI) + C/L loss of pain & temperature	Lateral medullary syndrome
Ptosis (III nerve palsy) + C/L loss of sensations	Benedict syndrome

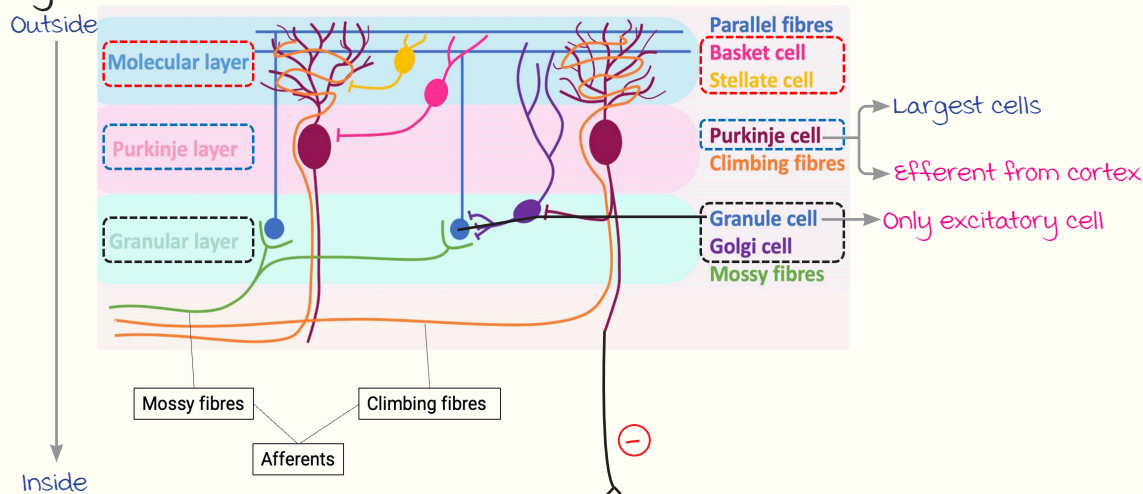
NEUROANATOMY : PART 2

----- Active space -----

Cerebellum

00:00:05

Layers of Cerebellar Cortex :



Deep cerebellar nuclei (In white matter)

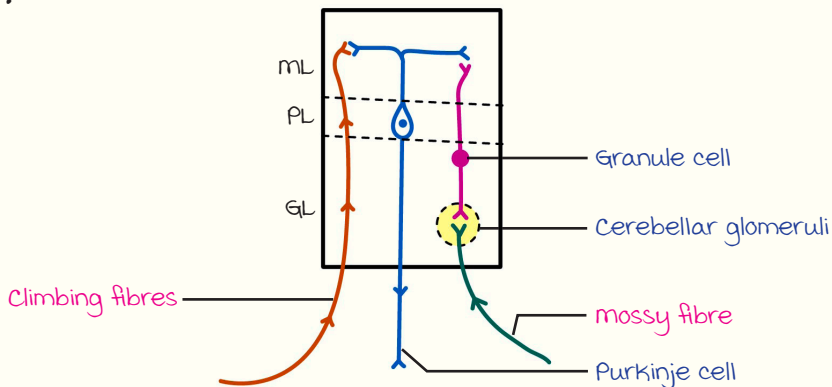
mnemonic : Doctor Eat Good Food

- Lateral
 - Dentate (Largest)
 - medial
 - Emboliform
 - Globose
 - Fastigial
- These are collectively known as the Nucleus interpositus.



Efferents from cerebellum

Afferents :



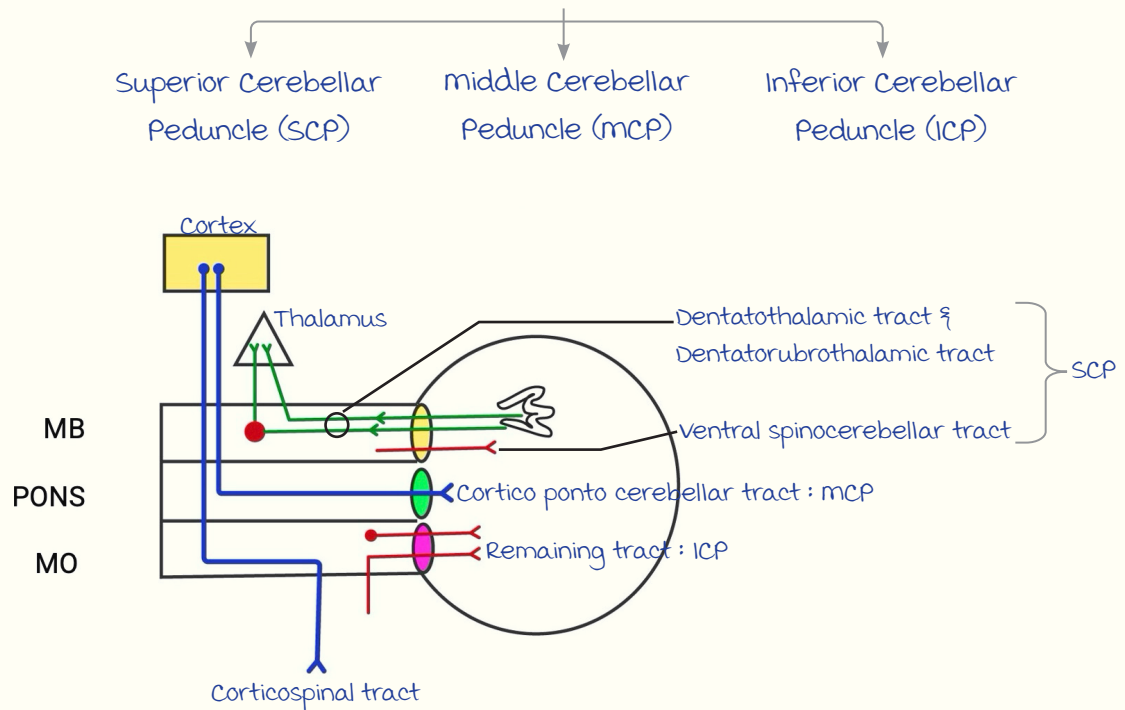
Climbing fibres :

- Terminates in molecular layer
- Eg :
 - Olivocerebellar tract
 - Paraolivocerebellar tract

mossy fibres :

- Terminates in granular layer
- Eg : Every other tract

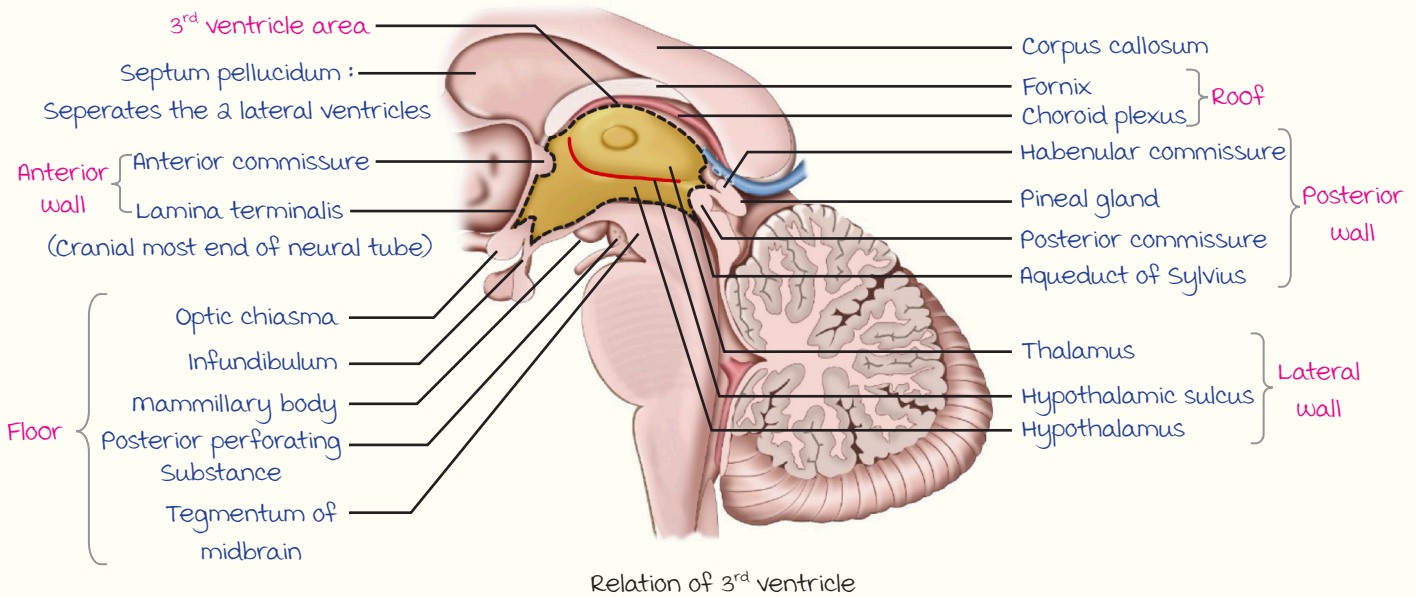
----- Active space ----- **Cerebellar Peduncles :**



Sections of the Brain & Blood Supply

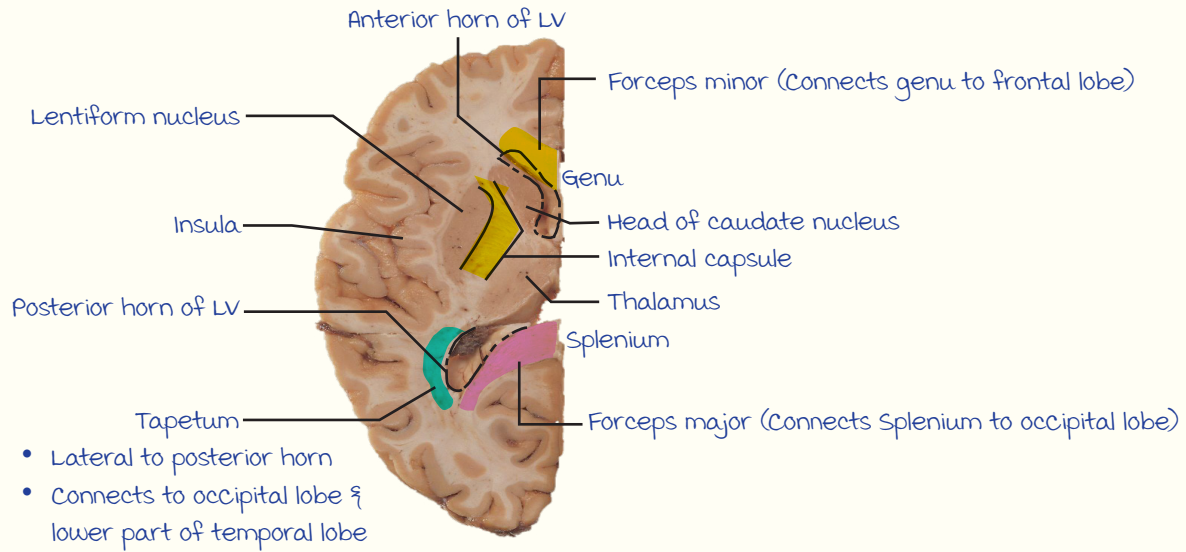
00:15:50

Sagittal Section :



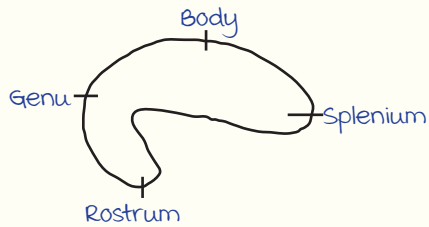
Transverse Section :

----- Active space -----



Corpus Collosum :

Parts :

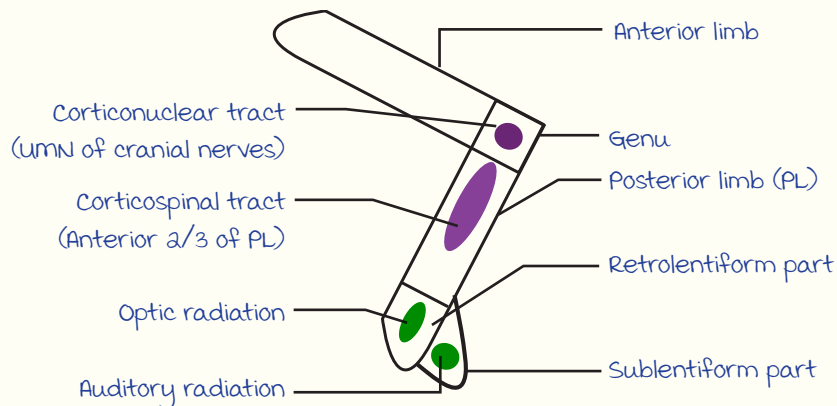


Fibres :

- Forceps major.
 - Forceps minor.
 - Tapetum.
- } Commissural fibres

Internal Capsule :

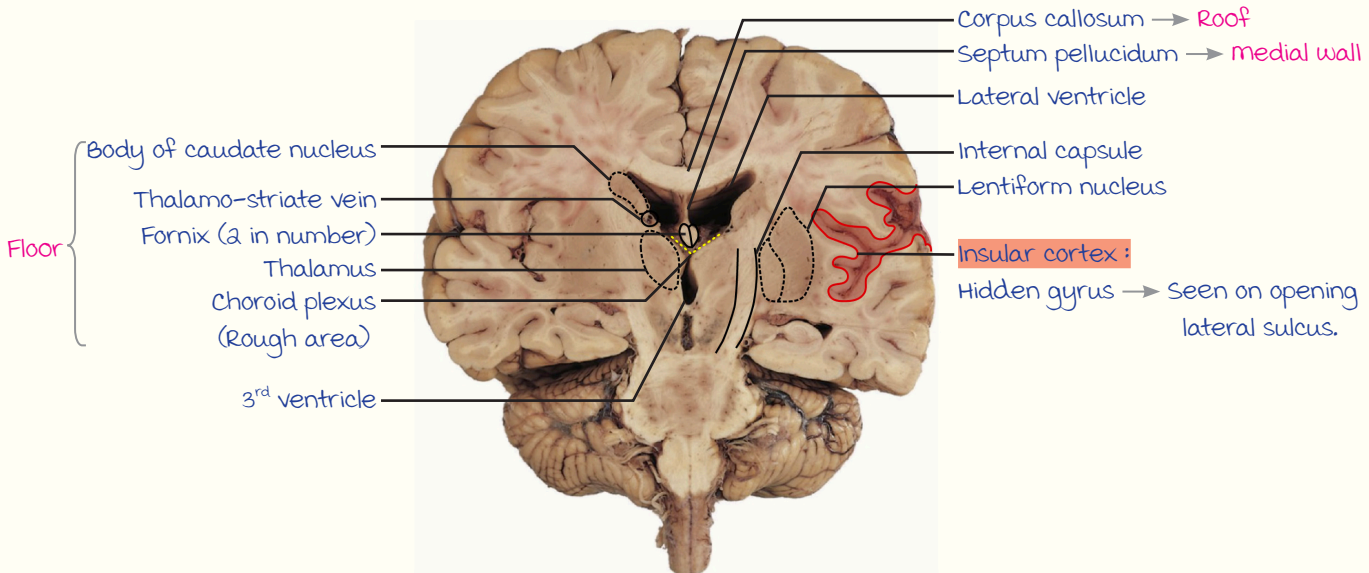
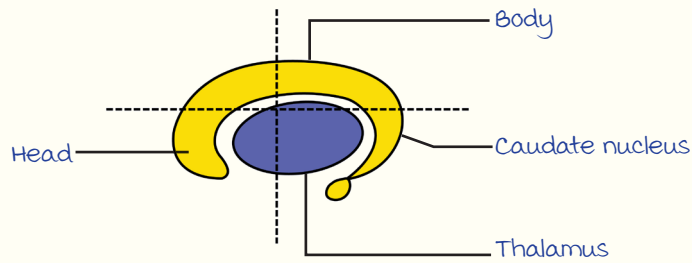
major tracts :



Blood supply :

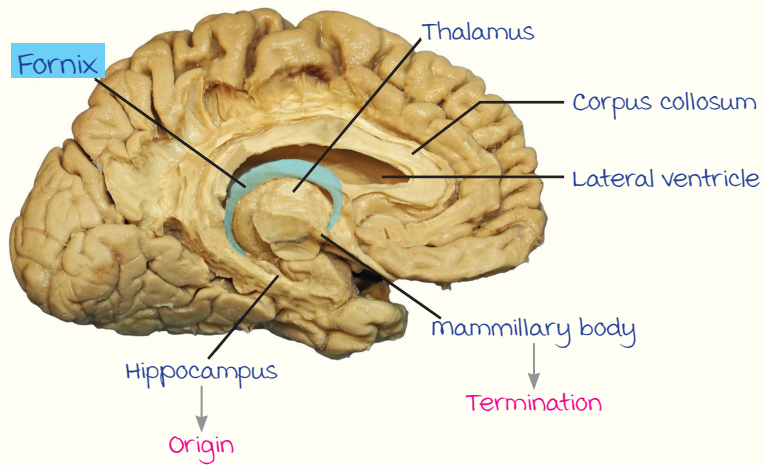
- Genu
 - Posterior limb
- } Charcot's artery → Branch of MCA.

----- Active space ----- **Coronal Section :**



Relations of lateral ventricle

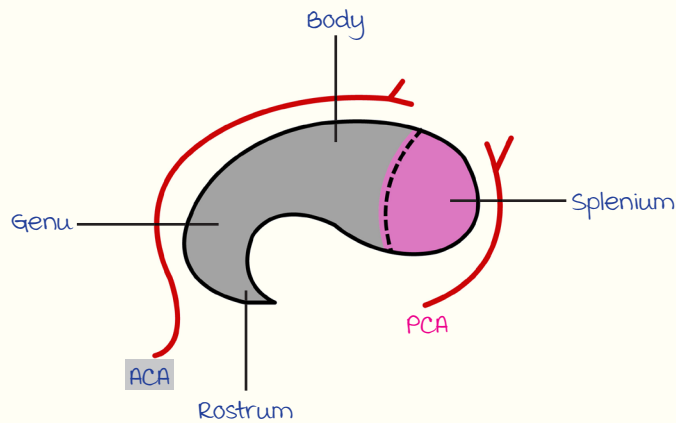
Fornix :



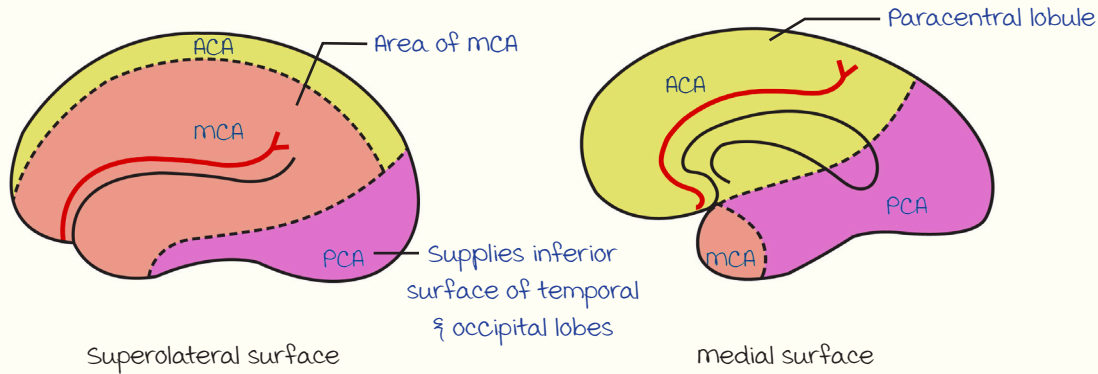
BLOOD SUPPLY

Corpus Callosum :

----- Active space -----



Blood Supply to the Cortex :



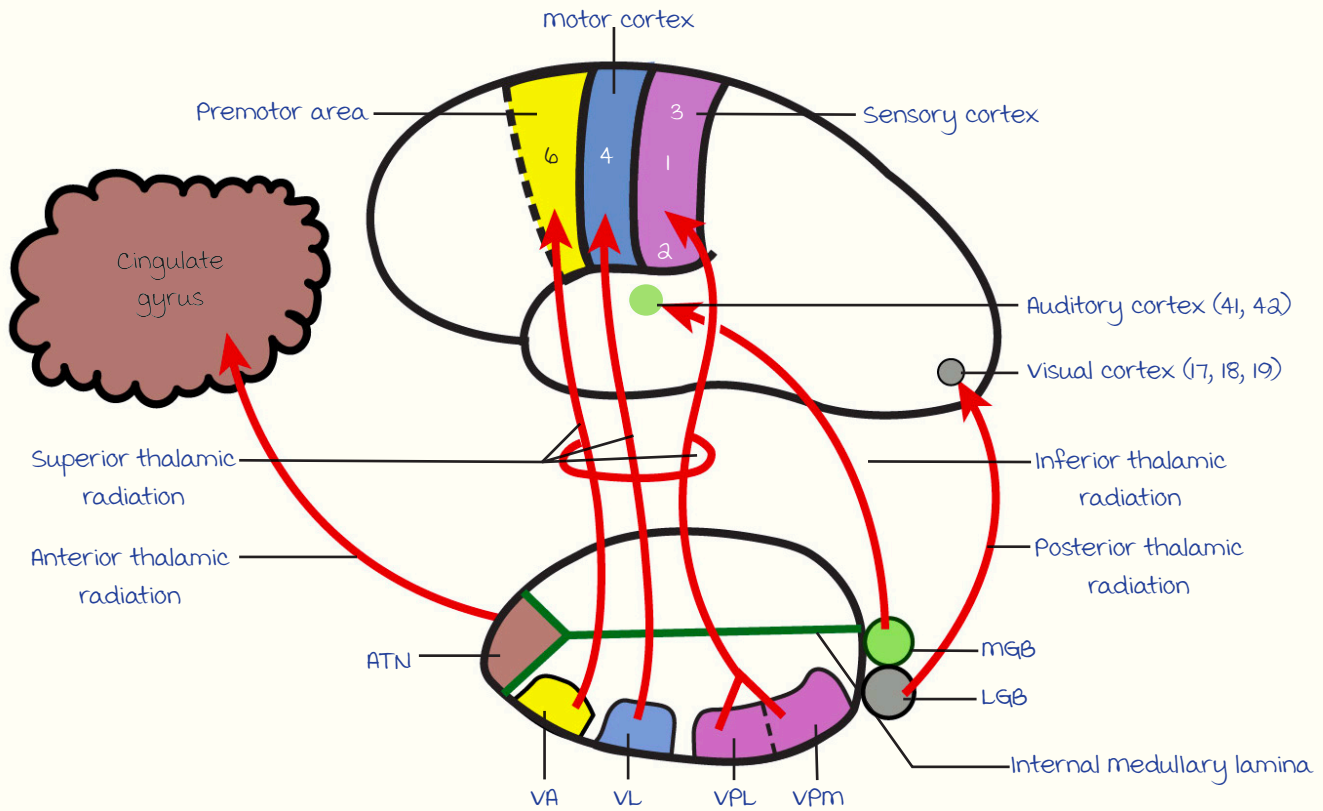
Area	Blood supply
<ul style="list-style-type: none"> • Broca's area (44, 45) • Wernicke's area (22, 30, 40) 	mCA
<ul style="list-style-type: none"> • Visual cortex 	PCA
<ul style="list-style-type: none"> • Lower limb (Sensory & motor) • Paracentral lobule (Highest centre for micturition & defecation) <p>Applied aspect : ACA stroke → C/L LL paralysis, Incontinence</p>	ACA

----- Active space -----

Thalamic Radiations Projecting on Cortex

00:53:02

Nuclei & their Output :



Nuclei & their Input :

Nuclei	Input
ATN	mammillary bodies $\xrightarrow{\text{via}}$ mammi-lo-thalamic tract
ventroanterior (VA)	Globus pallidus $\xrightarrow{\text{via}}$ Pallidothalamic tract
ventro lateral (VL)	<ul style="list-style-type: none"> Dentato-thalamic tract Dentato-rubrothalamic tract
ventroposterolateral (VPL)	<ul style="list-style-type: none"> medial lemniscus Spinal lemniscus } Sensations from limbs
ventroposteromedial (VPM)	<ul style="list-style-type: none"> Trigeminal lemniscus : Sensations from mouth & face Nucleus of Tractus Solitarius : visceral sensations

UPPER LIMB : PART 1

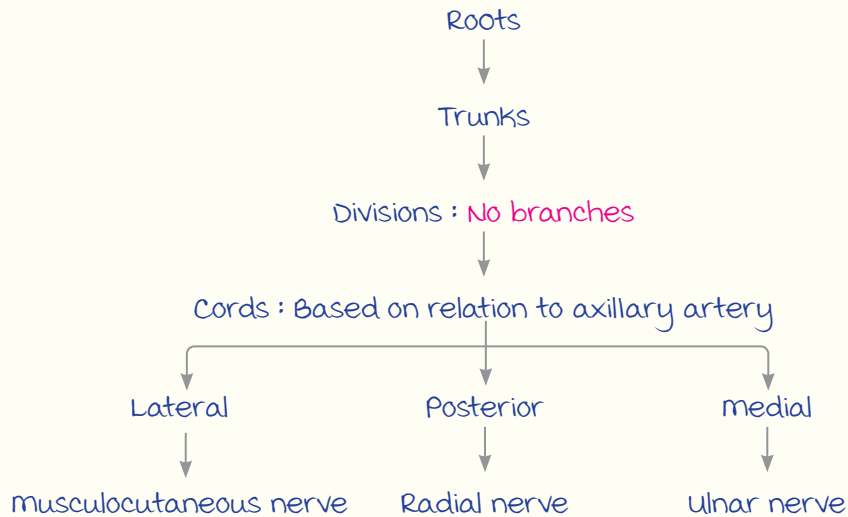
----- Active space -----

Brachial Plexus

00:00:05


Root value : C5, C6, C7, C8, T1.

Formation :



Note :

median nerve : Lateral + medial cord.

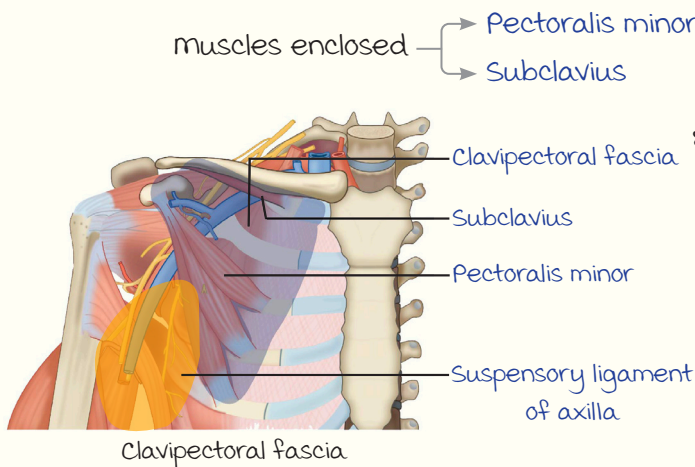


----- Active space ----- **Injuries To The Brachial Plexus :**

	Erb's palsy	Klumpke's palsy
Level of injury	Upper trunk	Lower trunk
Root value	C5, C6	C8, T1
Nerve involved & muscles affected	1. Axillary N. (C5, C6) ↓ Deltoid. 2. musculocutaneous nerve (C5, C6, C7) ↓ • Biceps (C5, C6). • Brachialis (C5, C6). • Coracobrachialis : Spared d/t C7 innervation.	1. Ulnar N. + median N. + Radial N. ↓ • Intrinsic muscles of hand (Interossei & lumbricals). 2. T1 sympathetic N. : ↓ Sympathetic loss on face.
Deformity & manifestation	Policeman's tip/waiter's tip hand/Porter's tip hand deformity : • Adducted shoulder. • Extended elbow. • Pronated forearm.	1. Complete claw hand • Hyperextension at MCP joint. • Flexion at IP joint. 2. Horner's syndrome.

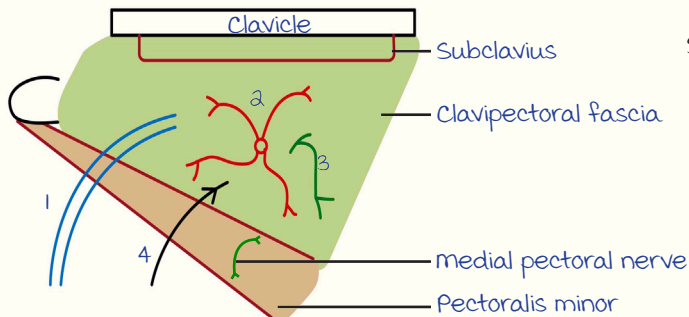
Clavipectoral Fascia

00:13:15



Extensions :

- Superior : Continues with investing layer (Posterior layer) of deep cervical fascia.
- Inferior : **Suspensory ligament of axilla.**



Structures piercing clavipectoral fascia :

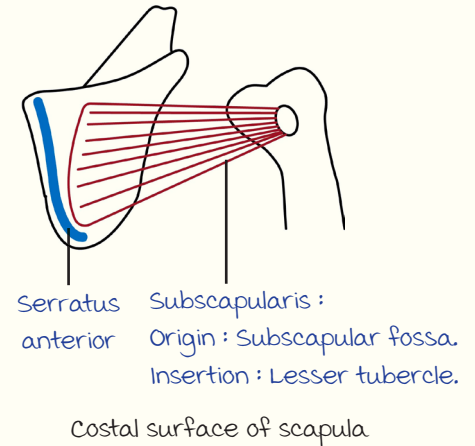
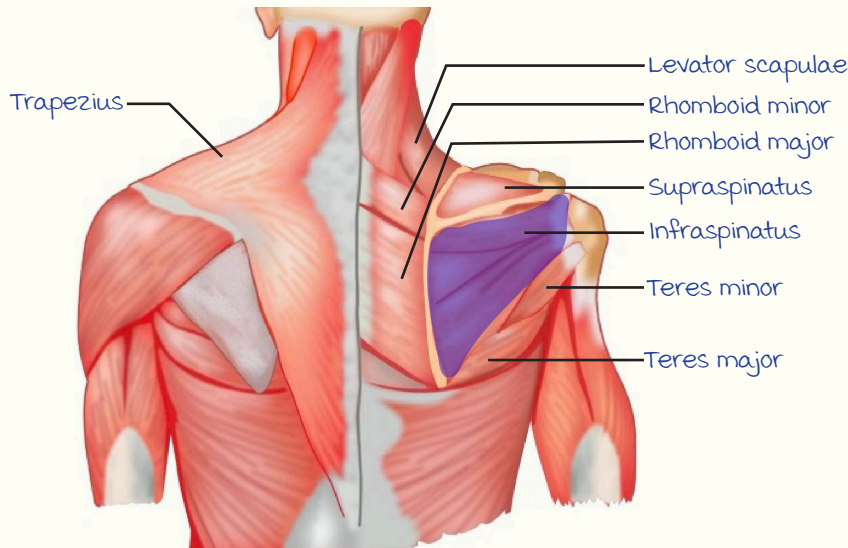
1. Cephalic vein.
2. Thoracoacromial trunk.
3. Lateral pectoral nerve.
4. Lymphatics.

Scapular Muscles & Cubital Fossa

00:19:47

----- Active space -----

SCAPULAR MUSCLES



Note :

Rotator cuff muscles :

1. Supraspinatus.
2. Infraspinatus.
3. Teres minor.
4. Subscapularis.

muscle	Action	Nerve supply
Trapezius	<ul style="list-style-type: none"> • upper fibres : Shrugging of shoulder. • middle fibres : Retraction of scapula. • upper & lower fibres : Outward rotation of scapula (Glenoid cavity rotated upwards) <p style="text-align: center;">↓ Overhead abduction.</p>	Spinal accessory nerve
Levator scapulae	Elevation of scapula	Dorsal scapular nerve (C ₅)
Rhomboid minor Rhomboid major	Retraction of scapula → Downward rotation of glenoid.	
Supraspinatus	0-15° Abduction at shoulder	-
Infraspinatus	External rotation at shoulder	-
Teres minor		
Teres major	Internal rotation	-
Serratus anterior AKA Boxer's muscle	Overhead abduction	Long thoracic nerve/ Nerve of Bell ✗ Injury ↓ Winging of scapula.
Subscapularis	Internal rotation at shoulder	Upper & lower subscapular nerve

----- Active space -----

CUBITAL FOSSA

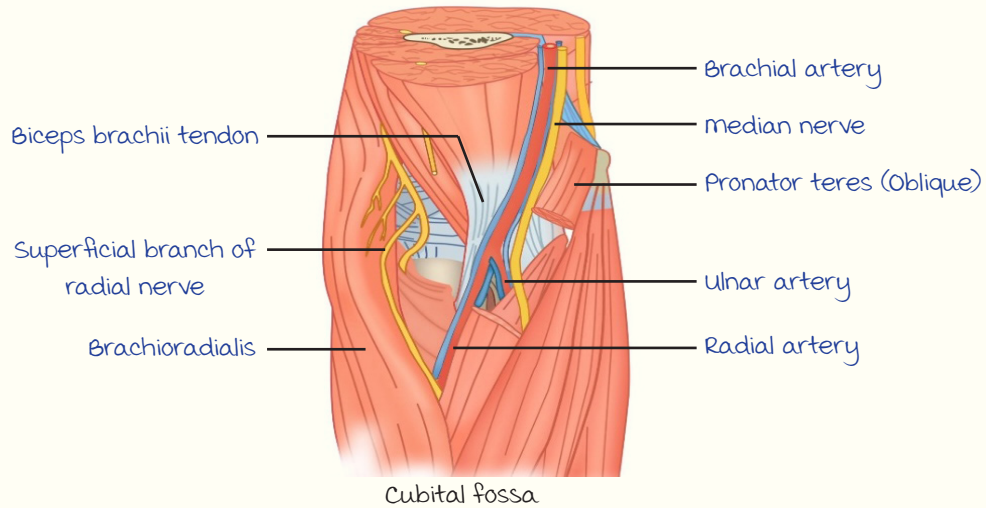
Boundaries —

- medial : Pronator teres.
- Lateral : Brachioradialis.

Contents :

medial → Lateral : **mBBS**.

- **m**edian nerve.
- **B**rachial artery.
- **B**iceps brachii tendon.
- **S**uperficial branch of radial nerve.

**Intrinsic Muscles Of Hand**

00:35:25

Thenar muscles :

1. Abductor pollicis brevis
 2. Flexor pollicis brevis
 3. Opponens pollicis
 4. Adductor pollicis → Ulnar nerve.
- } median nerve

Nerve injury	Function affected
median nerve (Irrespective of site)	Opposition of thumb
ulnar nerve	Adduction of thumb
Radial nerve	Extension of thumb

Note :

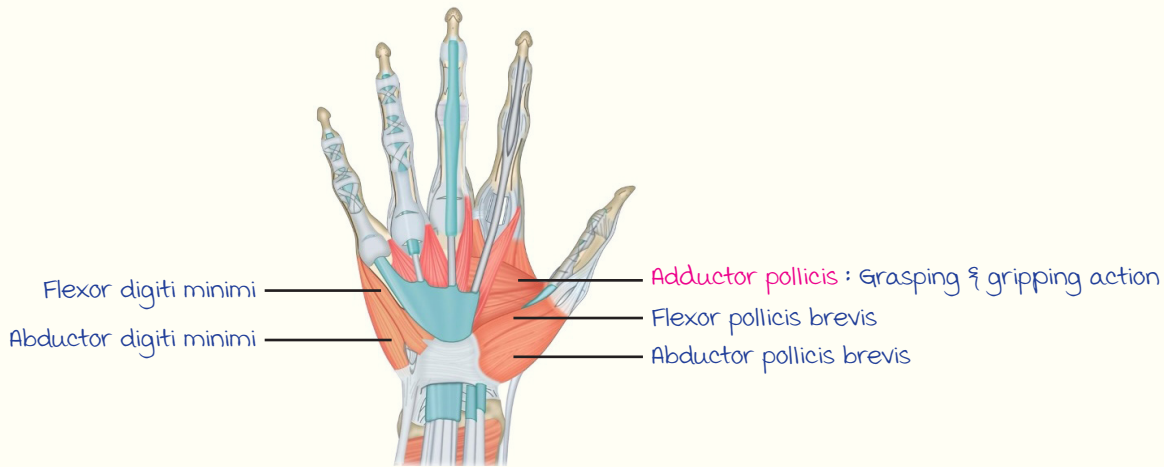
Thumb movements : Test all long nerves of upper limb.

Hypothenar muscles :

1. Abductor digiti minimi.
2. Flexor digiti minimi.
3. Opponens digiti minimi.
4. Palmaris brevis.
(Subcutaneous muscle)

Nerve supply : ulnar nerve.

----- Active space -----



Lumbricals :

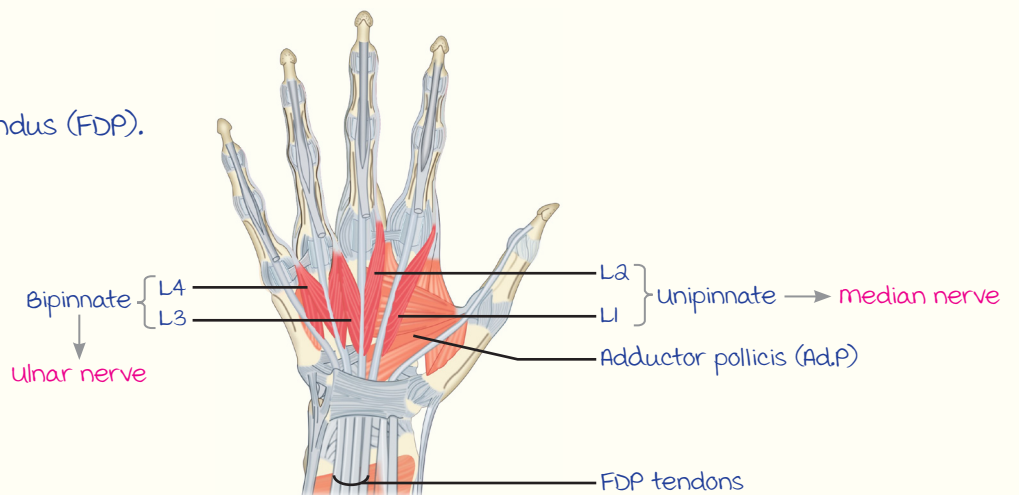
Tendon to tendon muscle.

Origin : Flexor digitorum profundus (FDP).

Insertion : Extensor digitorum.

Action :

- Flexion at MCP joint.
- Extension at IP joint.



Interossei :

Palmar interossei (PI) :

- 4 in number.
- unipinnate
- Supplied by ulnar nerve.

Dorsal interossei (DI) :

- 4 in number.
- Bipinnate
- Supplied by ulnar nerve.

Action : mnemonic

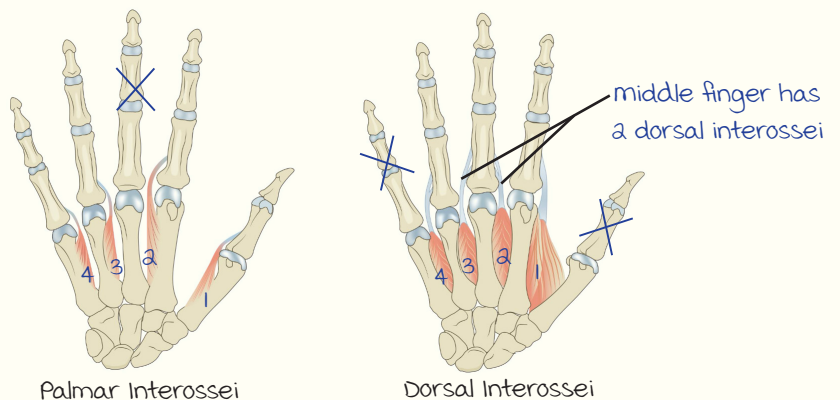
- PAD : Palmar interossei → Adduction of fingers.
- DAB : Dorsal interossei → Abduction of fingers.

Note :

- middle finger : Devoid of PI.
- Thumb & little finger : Devoid of DI.

Test :

- PI : Card test.
- DI : Egawa test.



UPPER LIMB : PART 2

----- Active space -----

Radial Nerve

00:00:08

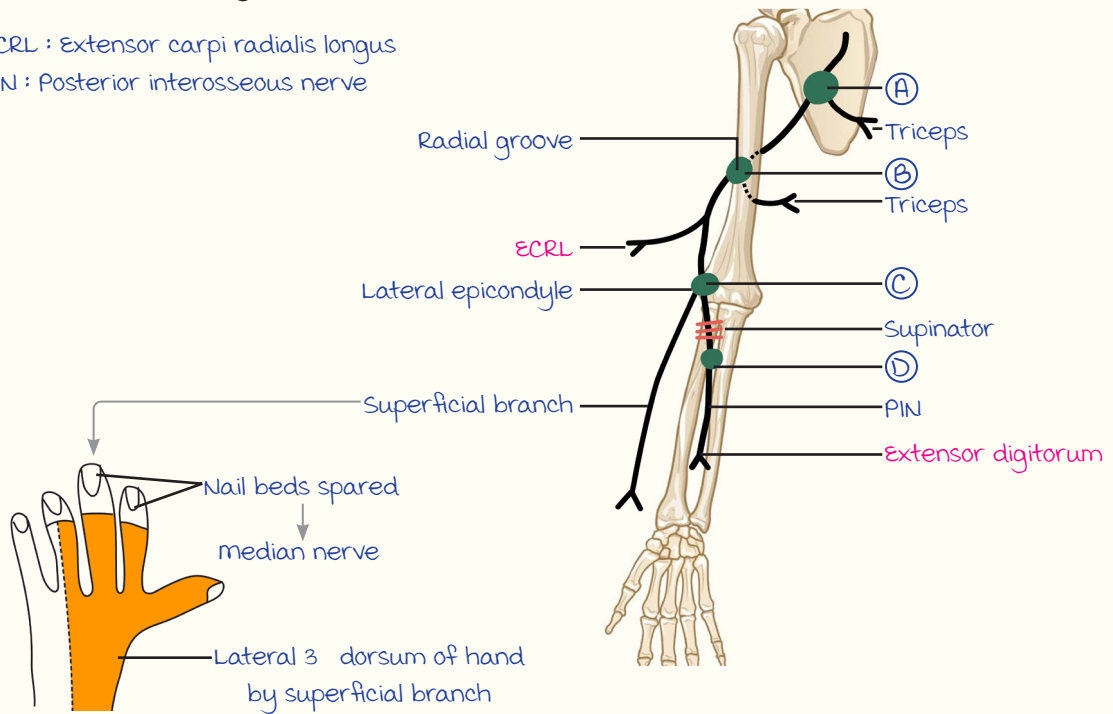
Origin : Posterior cord of brachial plexus.

Root value : C₅, C₆, C₇, C₈, T₁.

Course and Supply :

ECRL : Extensor carpi radialis longus

PIN : Posterior interosseous nerve



Radial Nerve Injuries :

	A → Crutch palsy : Axilla injury	B → Saturday night palsy : Radial groove	C → Lateral epicondyle fracture	D → Posterior Interosseous nerve injury (m/c cause : Radial head fracture)
Triceps injury	Elbow flexed	Partial injury : Weakness in elbow extension	Not involved	Not involved
wrist extensors	wrist drop	wrist drop	Weak extension at wrist <i>d/t ECRL sparing</i>	No wrist drop
Finger extensors	Finger drop	Finger drop	Finger drop	Finger drop
Superficial branch of radial nerve	Sensory loss at lateral 3 dorsum of hand	Sensory loss at lateral 3 dorsum of hand	Sensory loss at lateral 3 dorsum of hand	<i>No sensory loss</i>

Note : m/c injured medial/lateral epicondyle fracture → ulnar nerve.

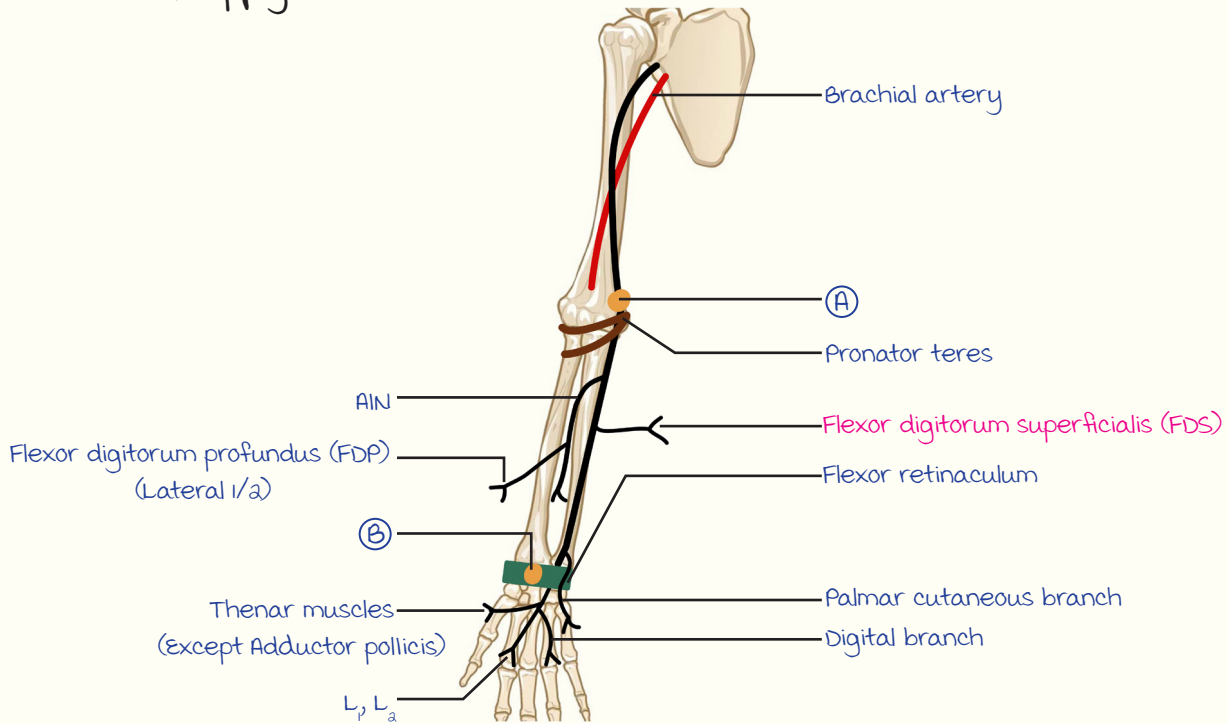
----- Active space -----

Median Nerve

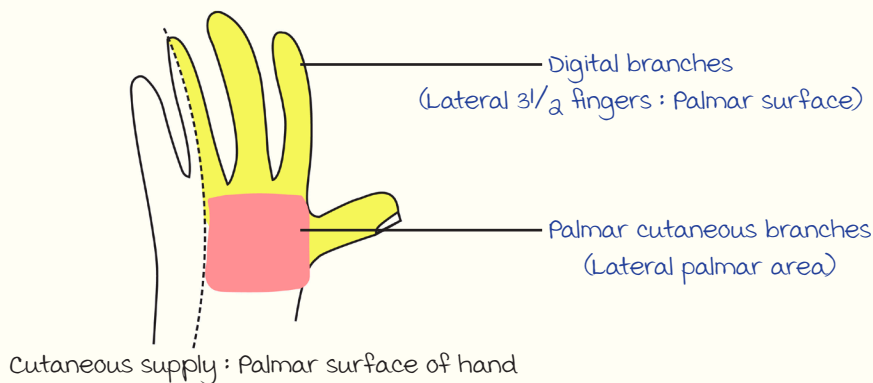
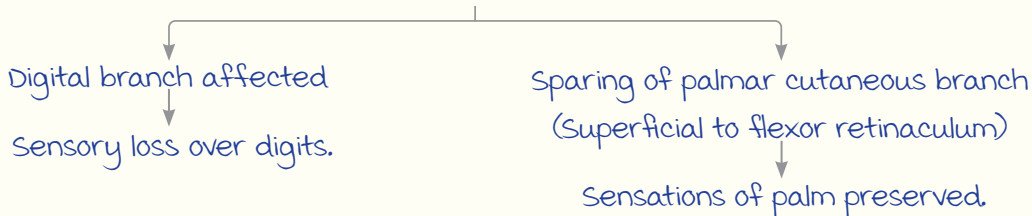
00:14:00

Root value : C₅, C₆, C₇, C₈, T₁.

Course and Supply :



Applied aspect : Carpal tunnel syndrome.



----- Active space ----- **Median Nerve Injury :**

	A : Higher injury	B : Lower injury
Thenar muscles	Ape thumb deformity	
FDS & FDP : (Lateral 1/2)	<p>While making a fist :</p> <ul style="list-style-type: none"> Pointing Index finger OR Benediction hand : Cannot flex index & middle finger 	Spared : Absent pointing index/ Hand of benediction
Palmar cutaneous branch	Sensory loss : Lateral 3 1/2 palmar surface of hand	Spared : No sensory loss in lateral 3 1/2 palmar surface of hand
Digital branches	Sensory loss : Lateral 3 1/2 fingers (Palmar surface)	

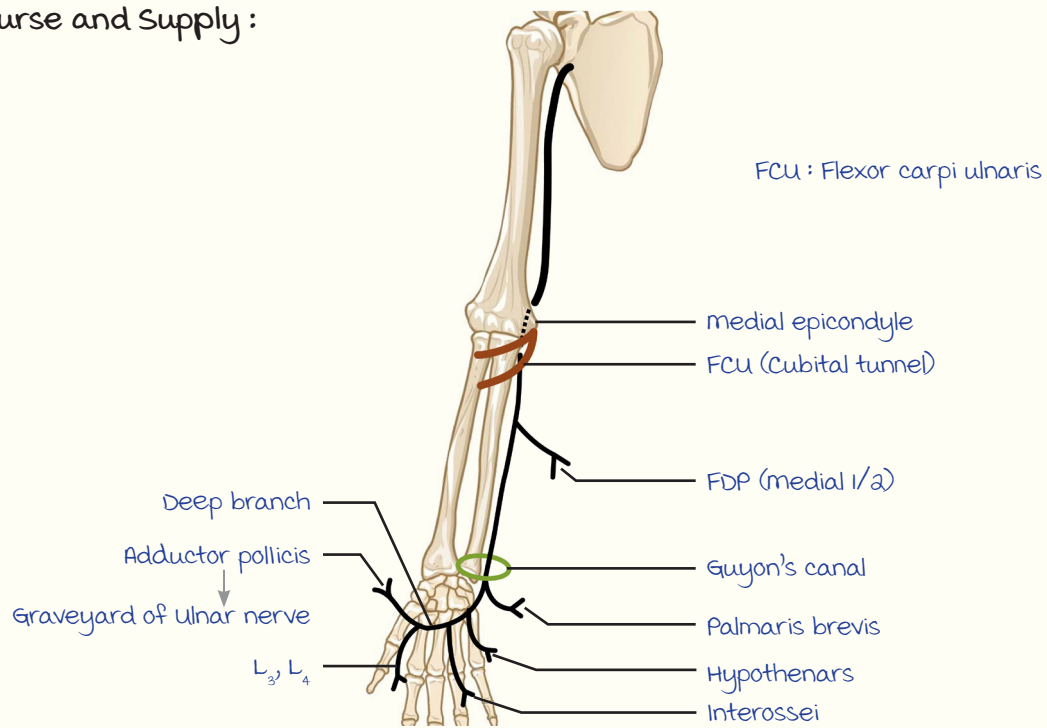
Ulnar Nerve

00:28:00

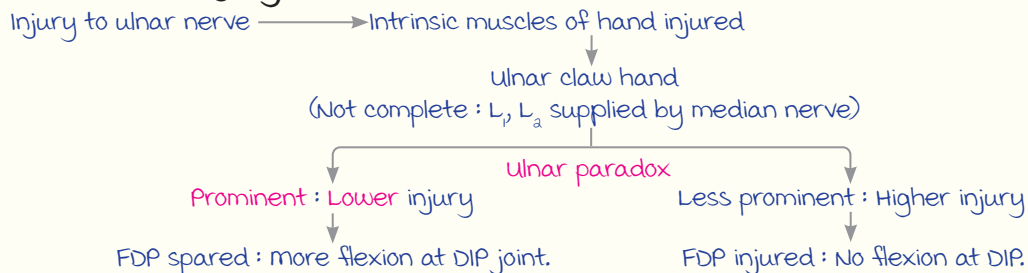
Origin : medial cord of brachial plexus.

Root value : C₇, C₈, T₁.

Course and Supply :



Ulnar Nerve Injury :



Test :

Book test → **Froment sign (+)** : Curling of thumb while trying to hold the book. (D/t compensatory action of flexor pollicis longus).

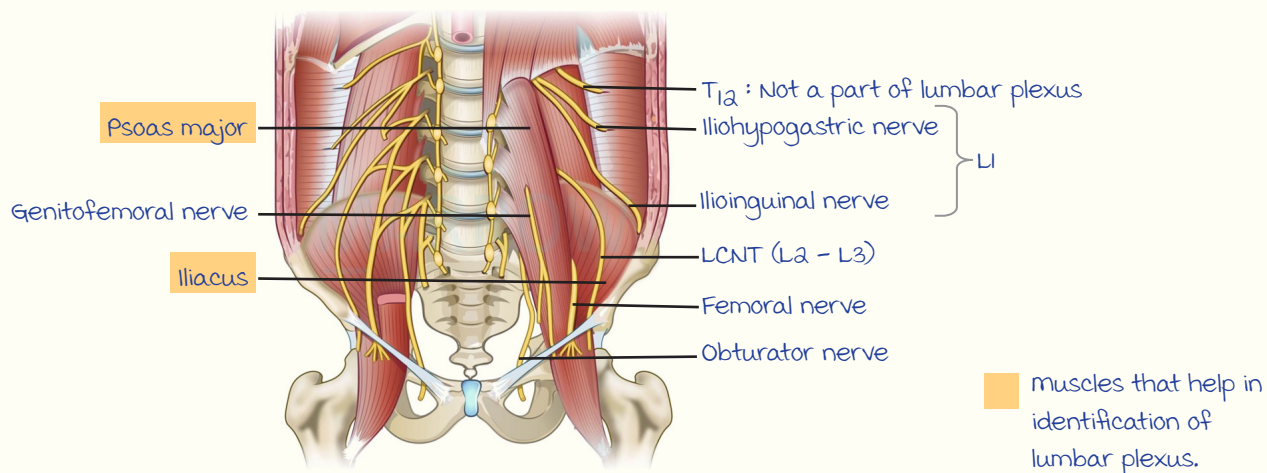
LOWER LIMB : PART 1

----- Active space -----

Lumbar Plexus & Iliotibial Band

00:00:20

LUMBAR PLEXUS



Applied anatomy : meralgia paresthetica.

- Occurs d/t compression of LCNT (Lateral Cutaneous Nerve of Thigh).
- Features : Sensory loss, tingling, numbness over lateral aspect of thigh.

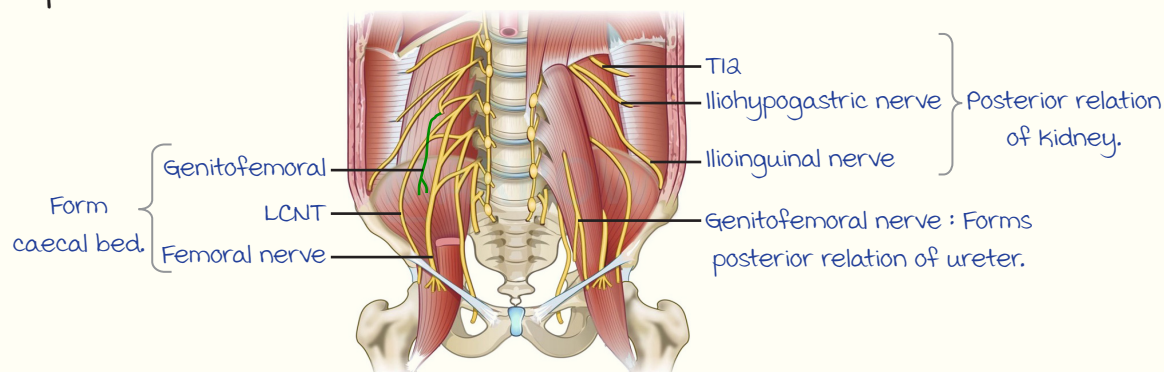
Genitofemoral Nerve :

Pierces but does not supply psoas major (Does not obey Hilton's law).

Branches :

Branch	Structure supplied	Importance
Femoral	Skin over femoral triangle	<ul style="list-style-type: none"> • Afferent for cremasteric reflex • Anesthetized in femoral vein cannulation
Genital	Cremasteric muscle	efferent for cremasteric reflex

Important Relations :



----- Active space -----

ILIOTIBIAL BAND

modification of fascia lata (Deep fascia of thigh).

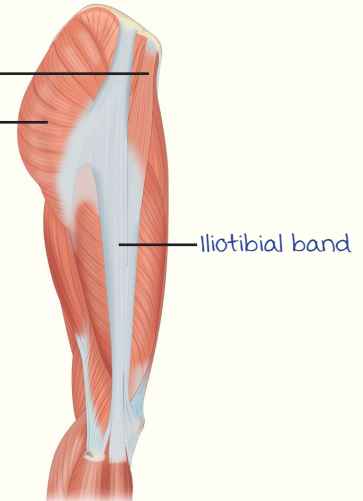
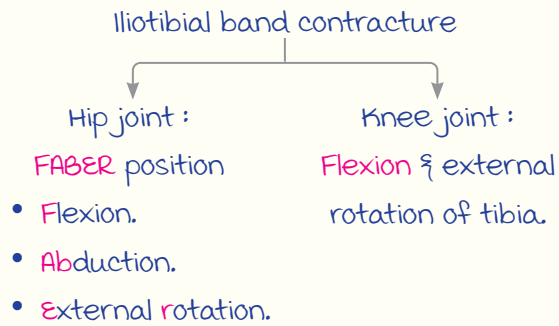
Origin : Tubercle of iliac crest.

Insertion : Lateral tibial condyle.

muscle insertions :

1. Tensor fascia lata. _____
2. Gluteus maximus. _____

Applied Anatomy :

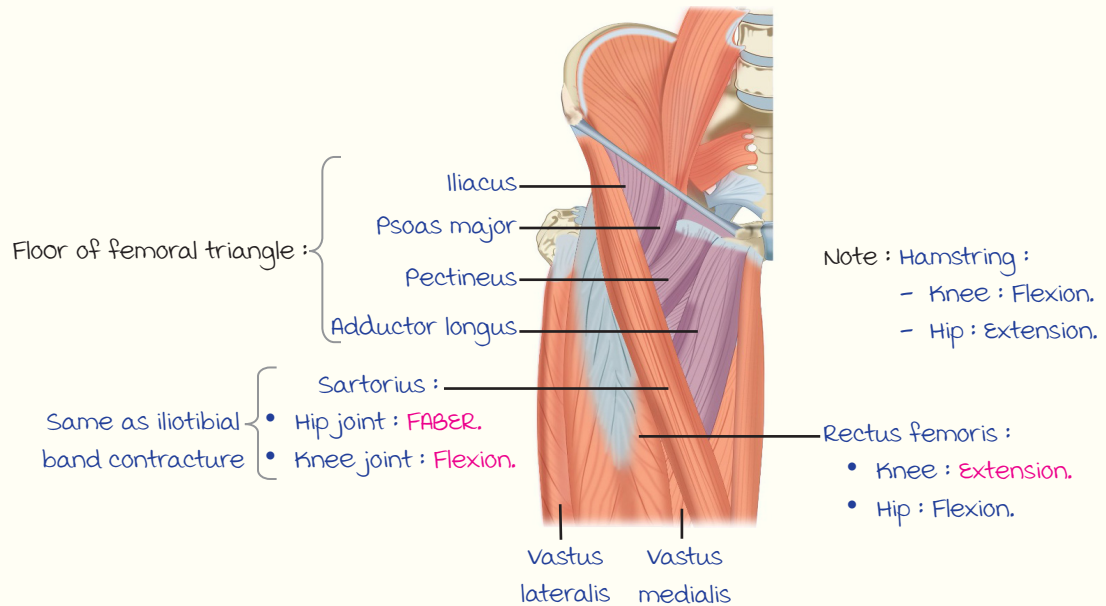


Anterior & Medial Compartment of Thigh

00:12:45

ANTERIOR COMPARTMENT : FEMORAL TRIANGLE

Boundaries of Femoral Triangle :



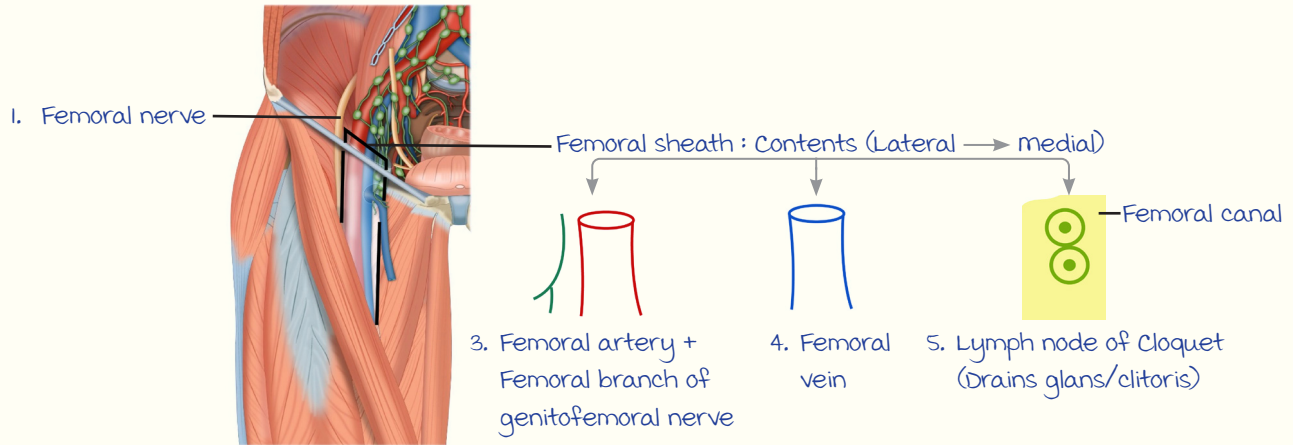
medial boundary : medial border of adductor longus.

Lateral boundary : medial border of sartorius.

Contents :

----- Active space -----

Femoral nerve + femoral sheath (2 + 3 + 4).

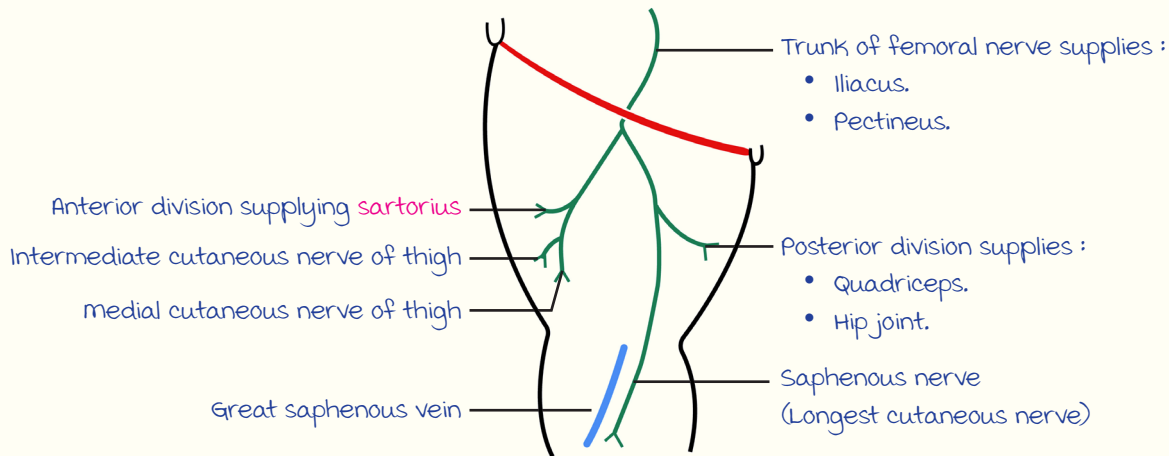


Formation of femoral sheath :

- Anterior : Fascia transversalis.
- Posterior : Fascia iliaca.

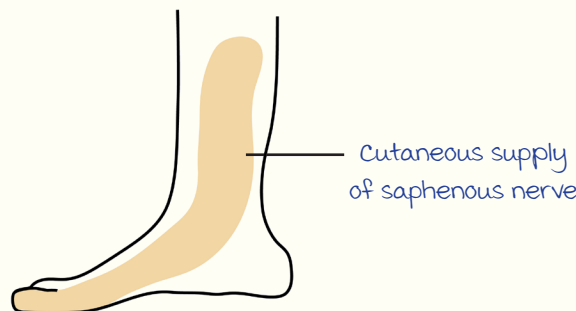
Femoral Nerve :

- Content of femoral triangle, lies outside femoral sheath.
- Root value : L2-L4 (Dorsal division of L2-L4).



Applied anatomy :

1. Saphenous vein grafting → Injury to saphenous nerve → Sensory loss on medial side of leg & foot up to great toe.



2. Referred pain of hip joint to medial side of leg & foot : D/t femoral nerve.

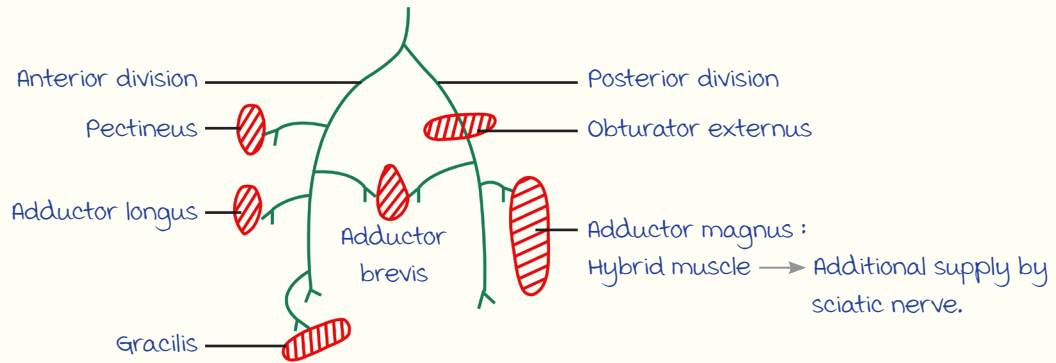
----- Active space -----

MEDIAL/ADDUCTOR COMPARTMENT OF THIGH

muscles :

1. Gracilis.
2. Obturator externus.
3. Adductor longus.
4. Adductor brevis.
5. Adductor magnus.

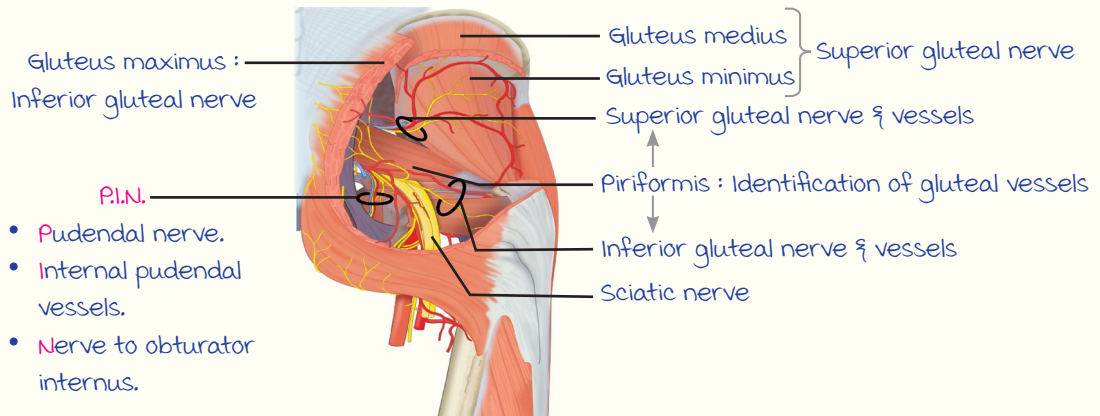
Nerve supply : Obturator nerve (ventral division of L2-L4).



Gluteal Region & Popliteal Fossa

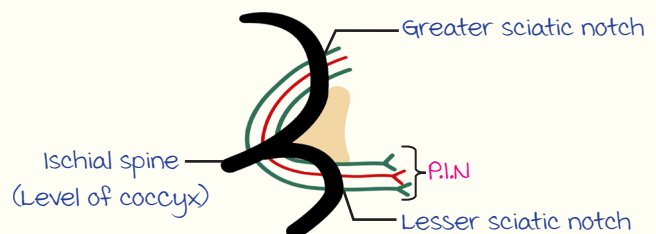
00:30:28

GLUTEAL REGION



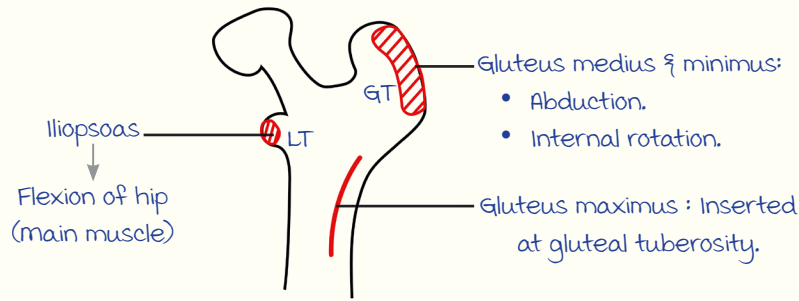
Applied Anatomy :

1. Injury to ischial spine
- ↓
- Pudendal nerve injury
- ↓
- Perineal muscles affected.



2. Trendelenburg sign :

----- Active space -----



- Injury to I/L superior gluteal nerve.
 - Injury to I/L gluteus medius/minimus.
 - I/L greater trochanter injury.
- } Inability to abduct & internally rotate
- ↓

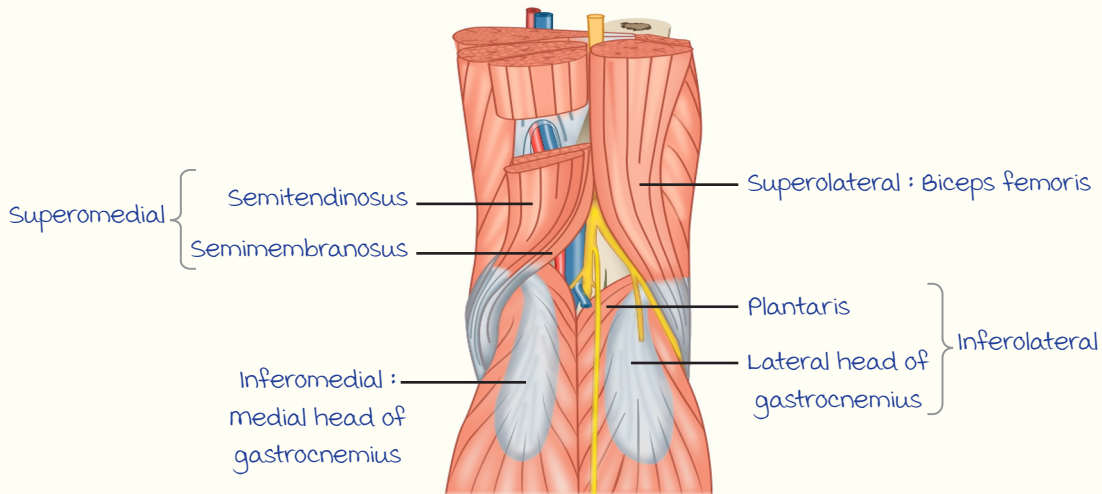
C/L pelvic drop.

↓

I/L lurching.

POPLITEAL FOSSA

Boundaries :



Contents :

1. Popliteal artery.
 2. Popliteal vein.
 3. Sciatic nerve
 - Tibial nerve.
 - Common peroneal nerve.
- } Deep

↓

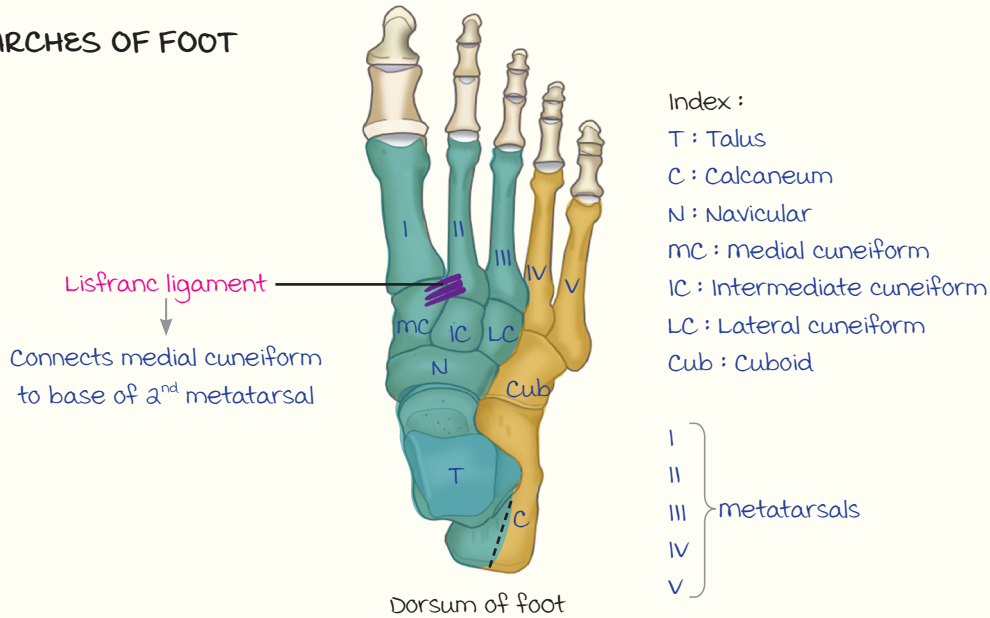
Superficial.



LOWER LIMB : PART 2

Arches of Foot & Ligaments of Ankle

00:00:06

ARCHES OF FOOT



	Bones	main joint
 medial longitudinal arch	9 bones : <ul style="list-style-type: none"> • Talus. • Navicular. • medial half of calcaneum. • I, II, III metatarsals. • medial, intermediate & lateral cuneiform. 	Talocalcaneonavicular (Ball & socket joint)
 Lateral longitudinal arch	4 bones : <ul style="list-style-type: none"> • IV, V metatarsal. • Cuboid. • Lateral half of calcaneum. 	Calcaneocuboid joint (Saddle joint)

LIGAMENTS

medial Side :

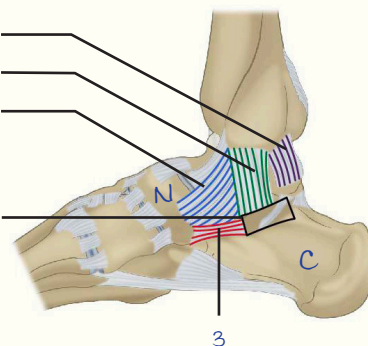
3 medial ligaments :

1. **Deltoid ligament :**

- Posterior fibres
- middle fibres
- Anterior fibres

2. **Sustentaculum tali**

- Sustains talus.
- extension of calcaneum.



3. **Plantar calcaneonavicular ligament**

(AKA Spring ligament) :

- Present on plantar surface.
- Extends b/w calcaneum & navicular tuberosity.
- Support head of Talus :
Ligament tear → Flat foot.

Deltoid ligament :

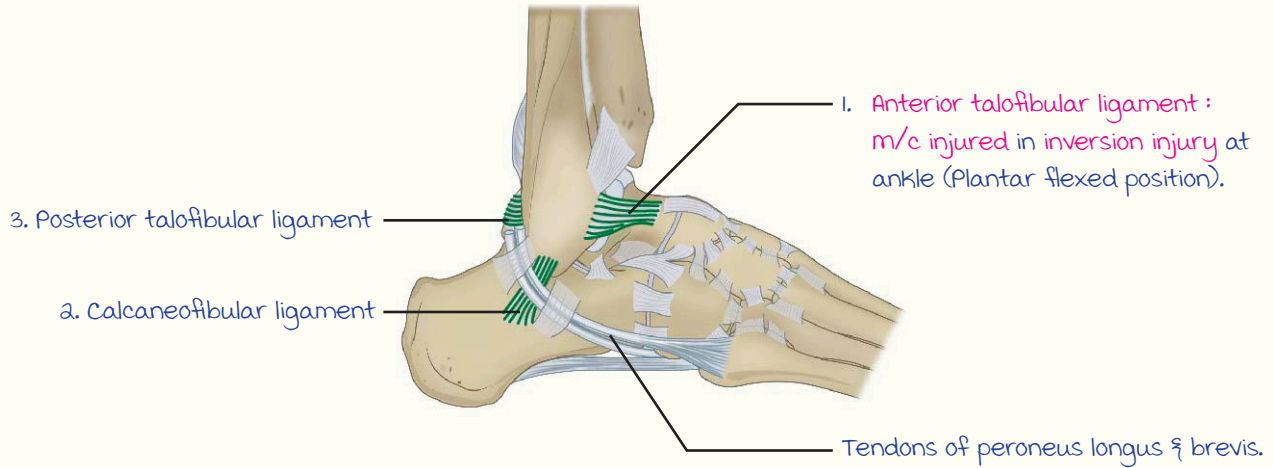
Strong ligament of ankle that prevents **eversion injury**.

----- Active space -----

Fibres	Insertion	Origin
Anterior	Navicular bone & spring ligament	Tibial malleolus
middle	Sustentaculum tali (Calcaneum)	
Posterior	Talus	

Lateral Side :

Lateral collateral ligament of ankle : Formed by 3 bands.



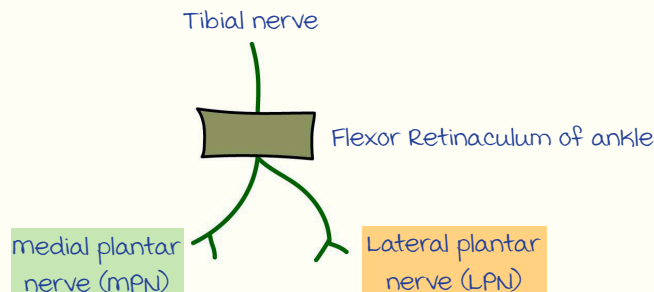
Sole of Foot

00:12:55

MUSCLES IN THE SOLE OF FOOT

4 layers ⊕ : Superficial → Deep.

Nerve Supply :



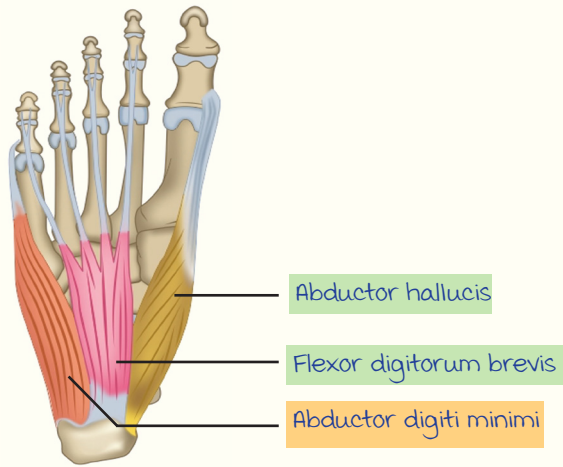
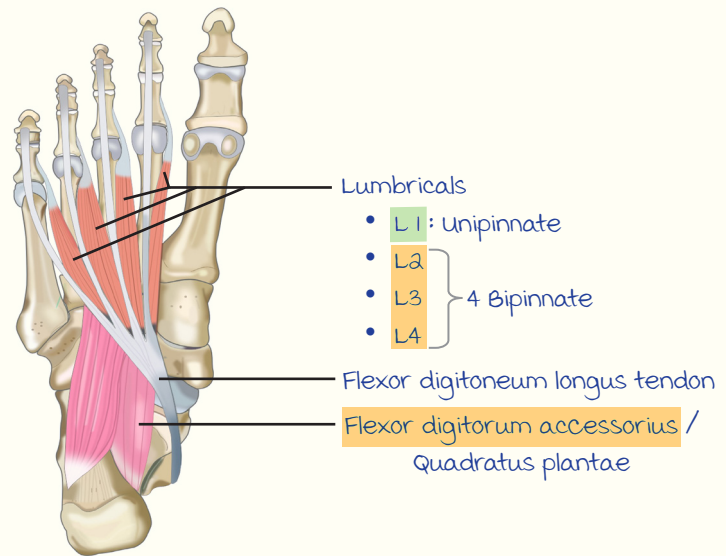
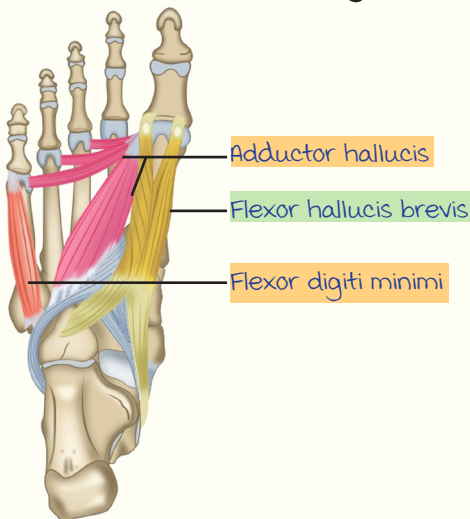
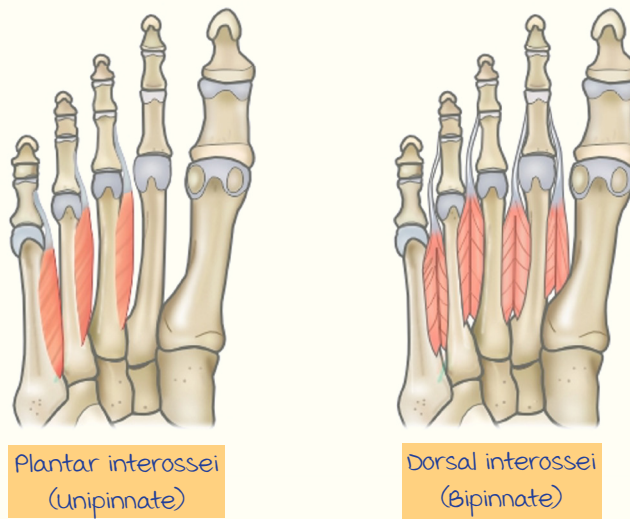
Note :

- Adductors
 - Bipinnates
 - Interossei
- Supplied by dominant nerve
- Hand : ulnar nerve.
 - Foot : Lateral plantar nerve.

----- Active space -----

Ist Layer :

Origin : Calcaneum.

**IInd Layer :****IIIrd Layer :****IVth Layer :****Sciatic Nerve**

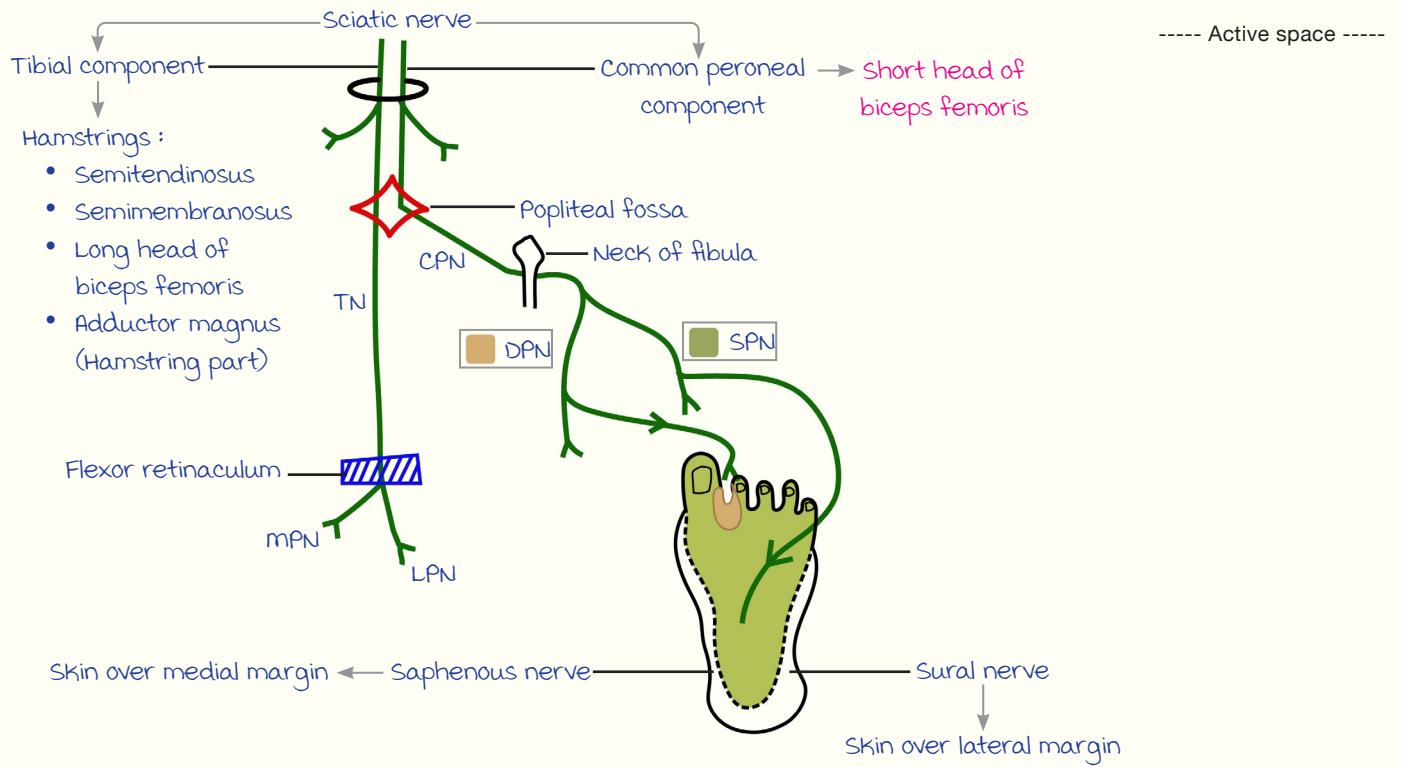
00:25:40

Root value : L4, L5, S1, S2, S3.

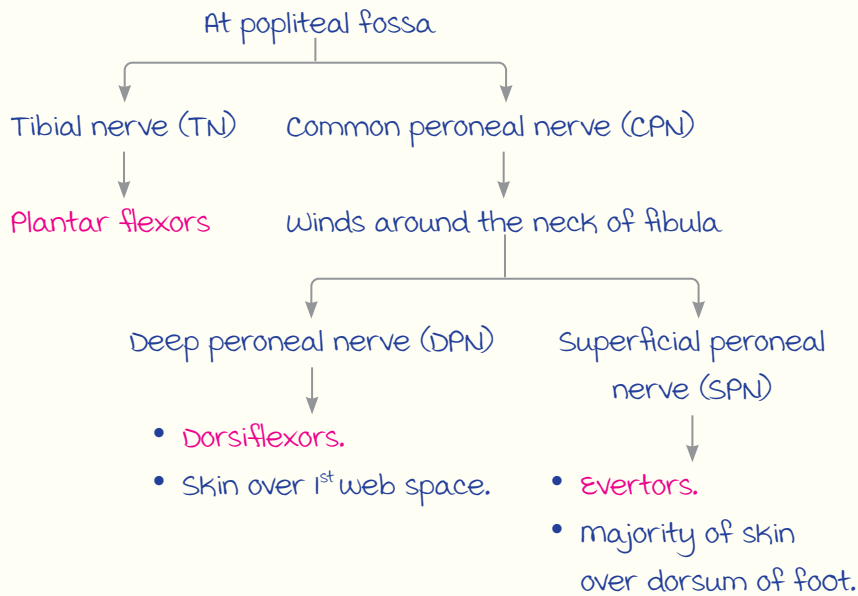
muscle innervation : Hamstring group.

Course :

- Sciatic nerve divides into 2 components :
 - Tibial component.
 - Common peroneal component.



Division :



Applied anatomy :

- Nerve injured during vein grafting
 - Great saphenous vein : Saphenous nerve.
 - Short saphenous vein : Sural nerve.
- # Neck of fibula → Injury to CPN
 - Loss of dorsiflexion → Foot drop
 - Eversion → Inverted foot
 } Equino varus
 ↓
 High stepping gait.